

CASE STUDY

Persistent varicella zoster virus infection following mRNA COVID-19 vaccination was associated with the presence of encoded spike protein in the lesion

Mayuko Yamamoto MD, PhD | Misaki Kase MD | Hozumi Sano MD | Reiko Kamijima | Shigetoshi Sano MD, PhD 

Department of Dermatology, Kochi Medical School, Kochi University, Nankoku, Japan

Correspondence

Shigetoshi Sano, Department of Dermatology, Kochi Medical School, Kochi University, Kohasu, Okocho, Nankoku, Kochi 780-8505, Japan.
Email: sano.derma@kochi-u.ac.jp

Abstract

Background: Since the campaign of vaccination against COVID-19 was started, a wide variety of cutaneous adverse effects after vaccination has been documented worldwide. Varicella zoster virus (VZV) reactivation was reportedly the most frequent cutaneous reaction in men after administration of mRNA COVID-19 vaccines, especially BNT162b2.

Aims: A patient, who had persistent skin lesions after BNT162b2 vaccination for such a long duration over 3 months, was investigated for VZV virus and any involvement of vaccine-derived spike protein.

Materials & Methods: Immunohistochemistry for detection of VZV virus and the spike protein encoded by mRNA COVID-19 vaccine. PCR analysis for VZV virus.

Results: The diagnosis of VZV infection was made for these lesions using PCR analyses and immunohistochemistry. Strikingly, the vaccine-encoded spike protein of the COVID-19 virus was expressed in the vesicular keratinocytes and endothelial cells in the dermis.

Discussion: mRNA COVID-19 vaccination might induce persistent VZV reactivation through perturbing the immune system, although it remained elusive whether the expressed spike protein played a pathogenic role.

Conclusion: We presented a case of persistent VZV infection following mRNA COVID-19 vaccination and the presence of spike protein in the affected skin. Further vigilance of the vaccine side effect and investigation for the role of SP is warranted.

KEYWORDS

mRNA COVID-19 vaccine, spike protein, varicella zoster virus reactivation, vasculitis

This is an open access article under the terms of the [Creative Commons Attribution-NonCommercial](https://creativecommons.org/licenses/by-nc/4.0/) License, which permits use, distribution and reproduction in any medium, provided the original work is properly cited and is not used for commercial purposes.

© 2022 The Authors. *Journal of Cutaneous Immunology and Allergy* published by John Wiley & Sons Australia, Ltd on behalf of The Japanese Society for Cutaneous Immunology and Allergy.

1 | INTRODUCTION

Global pandemic of severe acute respiratory syndrome coronavirus 2 (SARS-CoV-2 or COVID-19), which was spread from China in 2019, urged development of COVID-19 vaccines. Until now, a number of cutaneous reactions after COVID-19 vaccination has been reported worldwide, including injection site reaction or so called COVID arm, urticarial reaction, morbilliform rash, vesicopapular lesions, pityriasis rosea-like lesion, purpura, vasculitis, thrombus, ulcer, and reactivation of herpesviruses.^{1,2}

Previous study revealed that the most frequent skin reactions were COVID arm in women (38.1%) and varicella zoster virus (VZV) reactivation in men (20%).² The underlying pathomechanism for the mRNA COVID-19 vaccination-associated skin reactions (hereafter referred to as CVSRs) largely remains unknown. It should be noted that CVSRs resemble those associated with COVID-19 infection itself.¹⁻³ VZV reactivation frequently arises under immune-exhaustion, such as aging, or immunocompromised conditions caused by immunosuppressive drugs, HIV infection, or malignancies. Reports on VZV reactivation associated with both COVID-19 infection and COVID-19 vaccination suggested dysregulated cellular immunity against VZV to allow reactivation from latent state.^{2,4,5} Here, we present a case of persistent VZV infection after COVID-19 vaccination.

2 | CASE PRESENTATION

A 64-year-old man, who had rheumatoid arthritis (RA) under the treatments with prednisolone (5 mg daily), tacrolimus (1.5 mg daily), and methotrexate (10 mg weekly), developed painful skin eruptions in both legs and hands. The eruptions started 13 days after the first dose of mRNA COVID-19 vaccination, BNT162b2. The lesions were exacerbated after the second dose of BNT162b2 vaccination, and he was referred to our clinic 2 days later. At the first visit, there were vesicopapules in the legs, necrotic nodules in the dorsum of the right hand and the left popliteal fossa (Figure 1A). He did not have a fever or any systemic symptoms. Laboratory examination revealed no remarkable change in blood counts, liver, or renal function except for mild increase of d-dimer suggesting abnormal coagulation. Because the patient had painful vesicopapular lesions, we empirically treated him with valacyclovir at a dose of 1000mg daily for 5 days under the diagnosis of herpes simplex; however, it was marginally effective. Then, we took a biopsy from the necrotic nodule in the left popliteal fossa. Histopathology revealed necrotic epidermis and underlying occlusive vasculopathy in the middle to deep dermis with inflammatory infiltrates with neutrophils, leukocytoclasia, fibrin exudation, extravasated erythrocytes, and microthrombi (Figure 1B,C). Also, there were lymphocytic infiltrates into the subcutaneous fat tissue (Figure 1D). Histological diagnosis of necrotizing vasculitis was made. In 88 day of the disease onset, some of the vesicopapular lesions turned to be necrotic nodules (Figure 2A) and groups of vesicles on red macules newly developed in the both legs (Figure 2B). In addition, there was a tender, palpable, cord-like subcutaneous nodule in

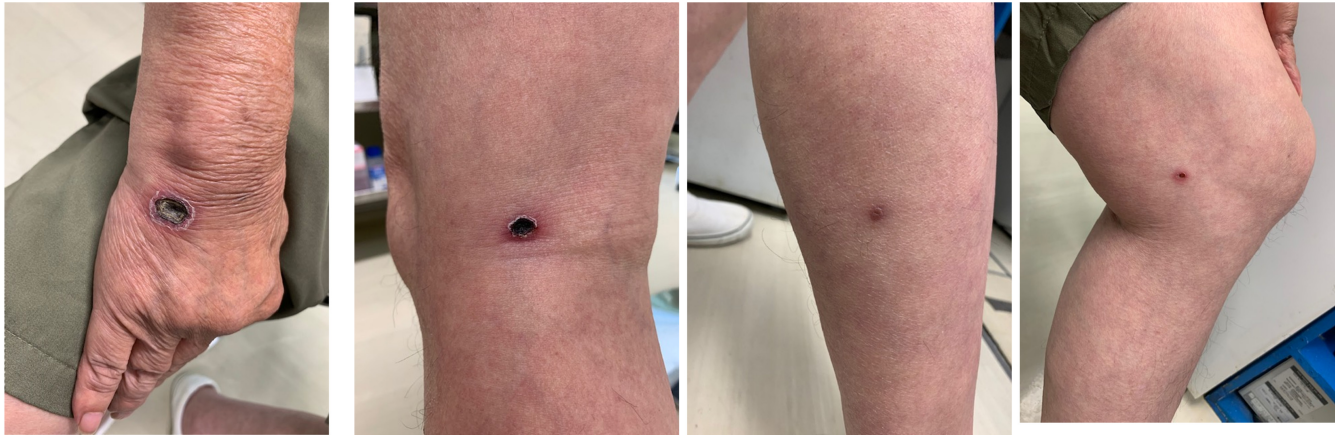
his right popliteal fossa, which we suspected to be superficial thrombophlebitis (Figure 2C). The vesicopapular eruption was biopsied and the histopathology revealed intraepidermal vesicles associated with giant cells and mononuclear cells infiltrating around vessels in the dermis (Figure 2D). Immunostaining with anti-VZV was positive for the degenerated keratinocytes in the vesicle, making a final diagnosis of VZV infection (Figure 2E). Accordingly, we confirmed VZV with PCR using extracted DNA from two biopsied specimens taken at the early and late stages of 2-month intervals, that is, necrotic nodules and vesicles, respectively (Figure 2F). We treated him with valacyclovir at a dose of 3000mg daily for 7 days, which improved all of his skin lesions. Together, we diagnosed him with persistent, multi-dermatomal VZV as long as 3 months. Therefore, sporadic necrotic nodules and painful subcutaneous nodules were also diagnosed as VZV-related small vessel vasculitis after mRNA COVID-19 vaccination as recently reported.⁶

Since we suspected the association of his lesions with mRNA COVID-19 vaccination, which doses were given 13 days prior to and 8 days after the onset of disease, any expression of the encoded spike protein in the lesion was investigated. Surprisingly, immunostaining with anti-coronavirus spike protein (SP) antibody revealed the SP expression in the intravesicular cells in the epidermis (Figure 3A,B) and endothelial cells of the inflamed vessels in the dermis (Figure 3A,C,D). It was not specified whether VZV infected keratinocytes co-expressed the SP protein since the double staining strategy was not performed in this study. In addition, the SP was also found in the endothelial cells of venules in the subcutaneous fat tissue underlying the herpetic vasculitis lesion (Figure S1). Note that the SP expression was not because of nonspecific staining of the antibody, since no signal was observed by the same antibody in the vesicular lesion in an mRNA COVID-19 vaccine-unrelated patient, while VZV expression was clearly detected (Figure S2).

3 | DISCUSSION

Generally, intact cellular and humoral immunity plays a major role in the protection against reinfection of viruses. However, recent study revealed that cellular but not humoral immunity was essential for the protection of VZV reactivation.⁷ VZV reactivation is reportedly one of the most frequent CVSRs.² Although the relationship between VZV reactivation and mRNA COVID-19 vaccination remains unclear, dysregulation of the cellular immunity may play a pathogenic role.^{2,4,5,8} Further, a recent study demonstrated a case of disseminated, multi-dermatomal VZV infection after vaccination.⁹ The present study represented a very rare case of persistent VZV infection exhibiting atypical clinical manifestations, including multi-dermatomal vesicles, necrotizing vasculitis and superficial thrombophlebitis-like lesions, which lasted as long as 3 months possibly associated with two doses of BNT162b2. COVID-19 infection-associated VZV reactivation was also described and included multi-dermatomal herpes zoster (HZ) and atypical HZ mimicking vasculitis,^{10,11} suggesting that the suppressive state of

(A)



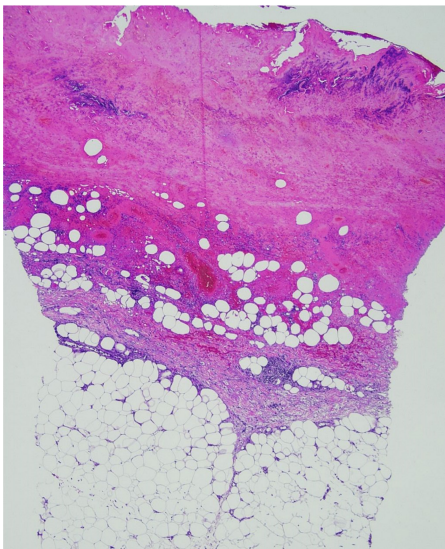
Hand (R)

popliteal fossa (L)

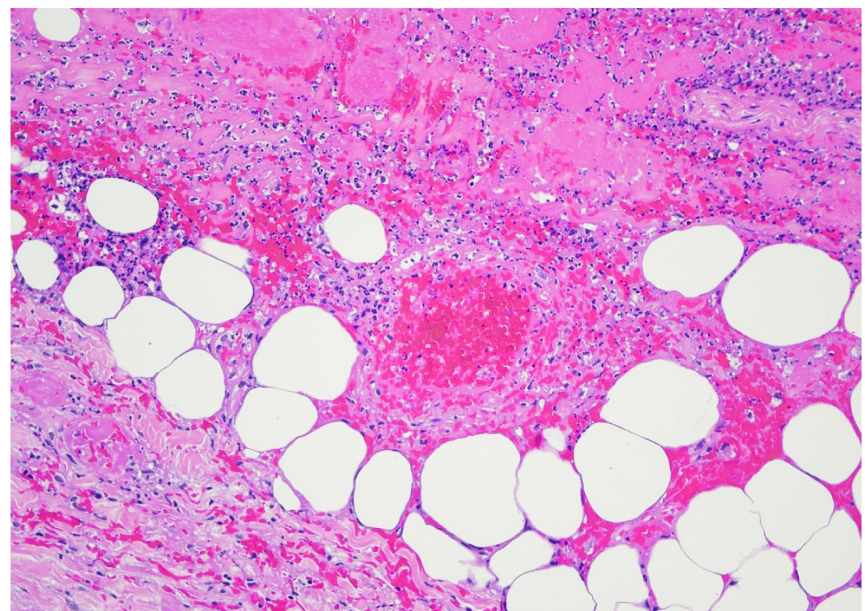
lower leg (R)

knee (L)

(B)



(C)



(D)

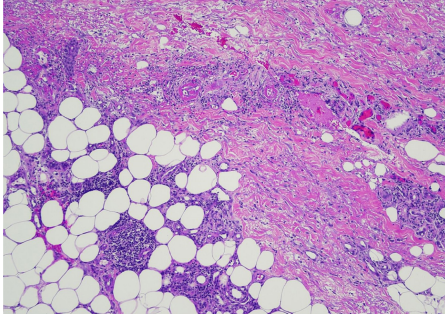


FIGURE 1 Clinical manifestations and histopathology. (A) Clinical features at the first visit (the day 10 of disease onset, 2 days after the second dose of BNT162b2). Painful necrotic nodules and vesicopapules in the extremities. R, right; L, left. (B) Histopathology of the necrotic nodule on the right popliteal fossa (the day 24 of disease onset). (B) Necrotic changes in the epidermis and dermis. (H&E staining. Original magnification $\times 40$). (C) Occlusive vasculopathy in the middle to deep dermis with inflammatory infiltrates of neutrophils, leukocytoclasia, fibrin exudation ($\times 200$). (D) Focal mononuclear cell infiltrates in the adipose tissue ($\times 100$)

T-cell-mediated immunity might be the shared condition induced by both COVID-19 infection and mRNA COVID-19 vaccine.⁴ Therefore, the SP could be the culprit for immunosuppression that allowed VZV

reactivation and its persistence, as well as skin vasculopathy and thrombosis.^{12,13} Recent literatures revealed that mRNA COVID-19 vaccination-associated VZV reactivation preferentially occurred in

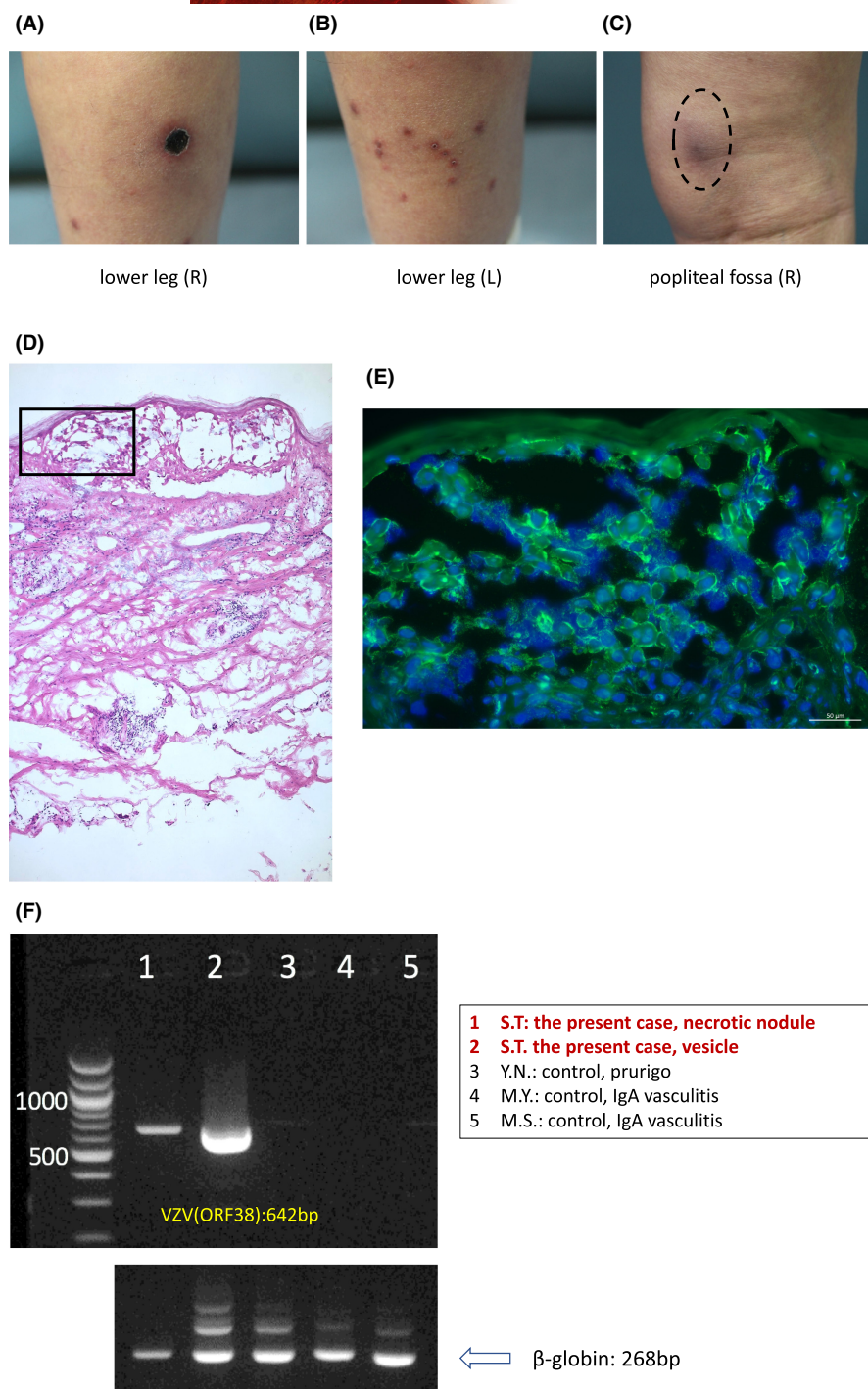


FIGURE 2 Clinical manifestations on the day 88 of disease onset and detection of VZV. (A) Necrotic nodule. (B) Group of vesicopapules. (C) Painful subcutaneous nodule (dotted circle). (D) Histopathology of the vesicopapule (H&E, ×100). Rectangle area was enlarged in (E) immunostained with anti-VZV antibody (×400). (F) Detection of VZV DNA by PCR. 1, 2; biopsied skins of the present case (S.T.) taken on the day 24 and 88 of disease onset, respectively. 3-5; controls as indicated. Beta globin gene was a loading control

patients with autoimmune diseases, including rheumatoid arthritis (RA) who were treated with immunosuppressive drugs.^{14,15} Our patient with RA had been taken prednisolone, tacrolimus, and methotrexate for over a decade, which possibly contributed to prolonged VZV infection after mRNA vaccination. Cases with persistent VZV activation longer than months have been described in three literatures, in which two cases were comorbid with HIV infection^{16,17} and another with severe immunocompromised condition as a result of chemotherapy for lymphoma, showing decrease of CD4 cell number down to less than 100/mm³.¹⁸ However, our patient was not immunocompromised clinically despite therapies for RA before COVID-19

vaccination, which therefore we suppose severely affected T cell immunity.

The detected SP in the affected skin in our patient has never been described before. Indeed, the vesicular keratinocytes and the underlying dermal endothelial cells in the vesicle lesion expressed the SP. In addition, the SP was also found in the endothelial cells in the vasculitis lesion. Although the pathogenic role of the SP in the lesion remained unclear, a plausible hypothesis was that the stabilization of RNA by substituting methyl-pseudouridine for all the uridine nucleotides for BNT162b2 might result in long-time production of the encoded SP from any cells, persistently affecting the

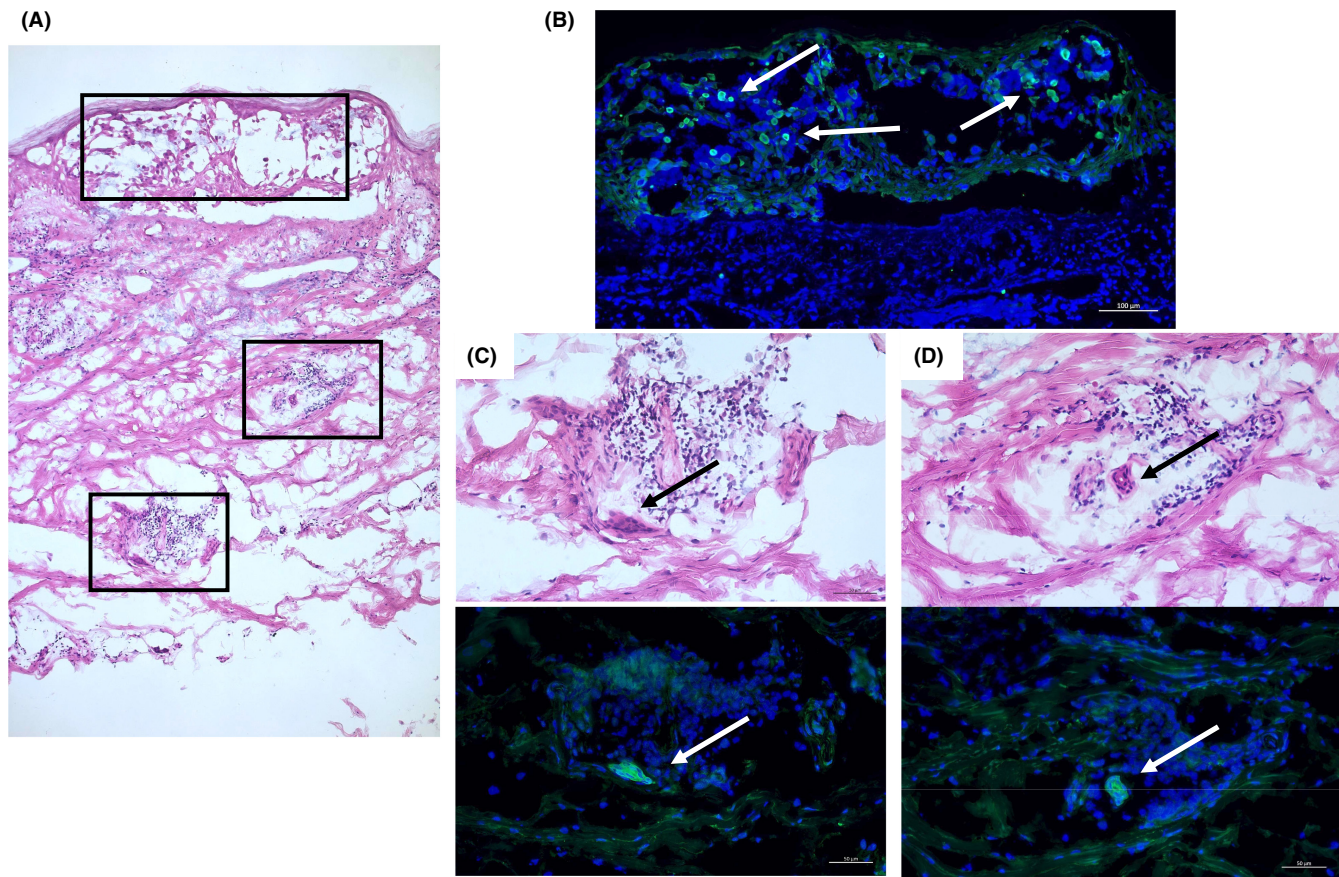


FIGURE 3 Detection of the spike protein (SP) of SARS-CoV-2. (A) H&E image (x100) of the same sample as Figure 2D highlighted with rectangle areas immunostained with anti-SP antibody (B–D). (B) SP expression in intravesicular cells (arrows, x200). (C,D) focal SP expression (white arrows, x400) in the inflamed vessel endothelial cells shown in the corresponding images with H&E staining (black arrows, x400)

microenvironment for the protective immune system including the skin. Weakness of our study was that the presence of SP was suggested only by immunohistochemistry. Therefore, any future scrutiny would be necessary for the identification of SP by using other methods, for example, Western blotting.

In summary, we presented a case of persistent VZV infection following mRNA COVID-19 vaccination and the presence of SP in the affected skin. Further vigilance of the vaccine side effect and investigation for the role of SP is warranted.

ACKNOWLEDGMENT

None.

CONFLICT OF INTEREST

Dr. Shigetoshi Sano is a member of the Journal of Cutaneous Immunology and Allergy Editorial Board. Management of the peer review process, and all editorial decision making, for this article was undertaken by the Editor in Chief. The other authors declare no conflict.

DECLARATIONS

Approval of the research protocol: No human participant was involved in this study.

Informed Consent: N/A.

Registry and the Registration No. of the study/trial: N/A.

Animal Studies: N/A.

ORCID

Shigetoshi Sano  <https://orcid.org/0000-0002-9812-0216>

REFERENCES

- McMahon DE, Amerson E, Rosenbach M, et al. Cutaneous reactions reported after Moderna and Pfizer COVID-19 vaccination: a registry-based study of 414 cases. *J Am Acad Dermatol*. 2021;85(1):46–55.
- Català A, Muñoz-Santos C, Galván-Casas C, et al. Cutaneous reactions after SARS-CoV-2 vaccination: a cross-sectional Spanish nationwide study of 405 cases. *Br J Dermatol*. 2022;186(1):142–52.
- Ohsawa R, Sano H, Ikeda M, Sano S. Clinical and histopathological views of morbilliform rash after COVID-19 mRNA vaccination mimic those in SARS-CoV-2 virus infection-associated cutaneous manifestations. *J Dermatol Sci*. 2021;103:124–7.
- Xu B, Fan CY, Wang AL, et al. Suppressed T cell-mediated immunity in patients with COVID-19: a clinical retrospective study in Wuhan, China. *J Infect*. 2020;81(1):e51–60.
- Katsikas Triantafyllidis K, Giannos P, Mian IT, Kyrtsonis G, Kechagias KS. Varicella zoster virus reactivation following COVID-19 vaccination: a systematic review of case reports. *Vaccines (Basel)*. 2021;9(9):1013. doi:10.3390/vaccines9091013

6. Nastro F, Fabbrocini G, di Vico F, Marasca C. Small vessel vasculitis related to varicella-zoster virus after Pfizer-BioNTech COVID-19 vaccine. *J Eur Acad Dermatol Venereol*. 2021;35(11):e745–7.
7. Asada H. VZV-specific cell-mediated immunity, but not humoral immunity, correlates inversely with the incidence of herpes zoster and the severity of skin symptoms and zoster-associated pain: the SHEZ study. *Vaccine*. 2019;37(44):6776–81.
8. Nanova K, Zlotogorski A, Ramot Y. Recurrent varicella following SARS-CoV-2 vaccination with BNT162b2. *Int J Dermatol*. 2021;60(9):1148–9.
9. Said JT, Virgen CA, Lian CG, Cutler CS, Merola JF, LeBoeuf NR. Disseminated varicella-zoster virus infections following messenger RNA-based COVID-19 vaccination. *JAAD Case Rep*. 2021;17:126–9.
10. Xu R, Zhou Y, Cai L, et al. Co-reactivation of the human herpesvirus alpha subfamily (herpes simplex virus-1 and varicella zoster virus) in a critically ill patient with COVID-19. *Br J Dermatol*. 2020;183(6):1145–7.
11. Mohaghegh F, Hatami P, Aryanian Z. Case of atypical disseminated herpes zoster in a patient with COVID-19: a diagnostic challenge in COVID era. *Clin Case Rep*. 2022;10(2):e05342.
12. Verdecchia P, Cavallini C, Spanevello A, Angeli F. The pivotal link between ACE2 deficiency and SARS-CoV-2 infection. *Eur J Intern Med*. 2020;76:14–20.
13. Aoki N, Saruta Y, Tanaka S, Nakajima R, Sano H, Sano S. Skin ulcer at the injection site of BNT162b2 mRNA COVID-19 vaccine. *J Dermatol*. 2021;48(12):e596–7.
14. Desai HD, Sharma K, Shah A, et al. Can SARS-CoV-2 vaccine increase the risk of reactivation of varicella zoster? A systematic review. *J Cosmet Dermatol*. 2021;20(11):3350–61.
15. Furer V, Zisman D, Kibari A, Rimar D, Paran Y, Elkayam O. Herpes zoster following BNT162b2 mRNA COVID-19 vaccination in patients with autoimmune inflammatory rheumatic diseases: a case series. *Rheumatology*. 2021;60(Si):Si90–Si95.
16. Ishiguro A, Takama H, Yanagishita T, Ohshima Y, Watanabe D. Efficacy of amenamevir for the treatment of herpes zoster in an immunocompromised patient: report of a case. *J Dermatol*. 2019;46(8):e270–1.
17. Pahwa S, Biron K, Lim W, et al. Continuous varicella-zoster infection associated with acyclovir resistance in a child with AIDS. *JAMA*. 1988;260(19):2879–82.
18. Bhalla P, Forrest GN, Gershon M, et al. Disseminated, persistent, and fatal infection due to the vaccine strain of varicella-zoster virus in an adult following stem cell transplantation. *Clin Infect Dis*. 2015;60(7):1068–74.

SUPPORTING INFORMATION

Additional supporting information can be found online in the Supporting Information section at the end of this article.

How to cite this article: Yamamoto M, Kase M, Sano H, Kamijima R, Sano S. Persistent varicella zoster virus infection following mRNA COVID-19 vaccination was associated with the presence of encoded spike protein in the lesion. *J Cutan Immunol Allergy*. 2022;00:1–6. <https://doi.org/10.1002/cia2.12278>