



Review Article

Acute ischemic stroke and vaccine-induced immune thrombotic thrombocytopenia post COVID-19 vaccination; a systematic review

Zahra Kolahchi^a, MohammadHossein Khanmirzaei^a, Ashkan Mowla^{b,*}^a Tehran University of Medical Sciences, Tehran, Iran^b Division of Stroke and Endovascular Neurosurgery, Department of Neurological Surgery, Keck School of Medicine, University of Southern California, CA, USA

ARTICLE INFO

Keywords:

COVID-19

Vaccination

Thrombosis

Thrombocytopenia

Acute ischemic stroke

Cerebral infarction

ABSTRACT

Introduction: One of the rare but potentially serious side effects of COVID-19 vaccination is arterial and venous thrombosis. Acute ischemic stroke (AIS) cases have been reported post COVID-19 vaccination. Herein, we systematically reviewed the reported cases of AIS after COVID-19 vaccination.

Method: This systematic review was conducted according to the Preferred Reporting Items for Systematic Reviews and Meta-Analyses (PRISMA) guideline. We searched PubMed and Scopus until April 14, 2022 to find studies that reported AIS post COVID-19 vaccination.

Results: We found 447 articles. From those, 140 duplicates were removed. After screening and excluding irrelevant articles, 29 studies (43 patients) were identified to be included. From all cases, 22 patients (51.1%) were diagnosed with AIS associated with Vaccine-induced immune thrombotic thrombocytopenia (VITT). Among AIS associated with VITT group, all received viral vector vaccines except one. The majority of cases with AIS and VITT were female (17 cases, 77.2%) and aged below 60 years (15 cases, 68%). Fourteen patients (32.5%) had additional thrombosis in other sites. Four of them (0.09%) showed concurrent CVST and ischemic stroke. Hemorrhagic transformation following AIS occurred in 7 patients (16.27%). Among 43 patients with AIS, at least 6 patients (14%) died during hospital admission.

Conclusion: AIS has been reported as a rare complication within 4 weeks post COVID-19 vaccination, particularly with viral vector vaccines. Health care providers should be familiar with this rare consequence of COVID-19 vaccination in particular in the context of VITT to make a timely diagnosis and appropriate treatment plan.

1. Introduction

The coronavirus disease-2019 (COVID-19) pandemic has posed serious challenges to the global public health, economics and social life [1–3]. Immunization of the whole population is a critical step in combating the COVID-19 pandemic. Unfortunately, adverse effects have been reported following vaccination [4,5]. Numerous COVID-19 vaccines have already been produced and released to the market, and several others are still undergoing clinical trials. The public's adoption of vaccinations is influenced by the information about vaccine safety and side effects [6,7]. The most common side effects following COVID-19 vaccination include a local reaction at the injection site and non-specific flu-like symptoms like fever, myalgia, fatigue and headache. These symptoms may appear immediately after immunization and disappear quickly [8]. There are also reports of rare but potentially

serious side effects such as arterial or venous thrombosis, Guillain-Barré syndrome (GBS), myocarditis, pericarditis, and glomerular disease [9,10]. AIS and cerebral venous sinus thrombosis (CVST) not only have been described as rare and serious neurological consequences of SARS-CoV-2 infection [11–24], but also have been outlined post COVID-19 vaccination [5,25–27]. AIS following COVID-19 vaccination has been reported in association with Vaccine-induced thrombotic thrombocytopenia (VITT) [28–30]. VITT has been previously reported with CVST post COVID-19 vaccination [30,31]. This systematic review aims to summarize reports of AIS following COVID-19 vaccination and provide insight into its pathophysiology, clinical picture and management.

2. Method

This systematic review was conducted according to the Preferred

* Corresponding author at: Division of Endovascular Neurosurgery, Department of Neurological Surgery, Keck School of Medicine, University of Southern California (USC), 1200 North State St., Suite 3300, Los Angeles, CA 90033, USA.

E-mail address: mowla@usc.edu (A. Mowla).

<https://doi.org/10.1016/j.jns.2022.120327>

Received 4 May 2022; Received in revised form 11 June 2022; Accepted 15 June 2022

Available online 20 June 2022

0022-510X/© 2022 Elsevier B.V. All rights reserved.

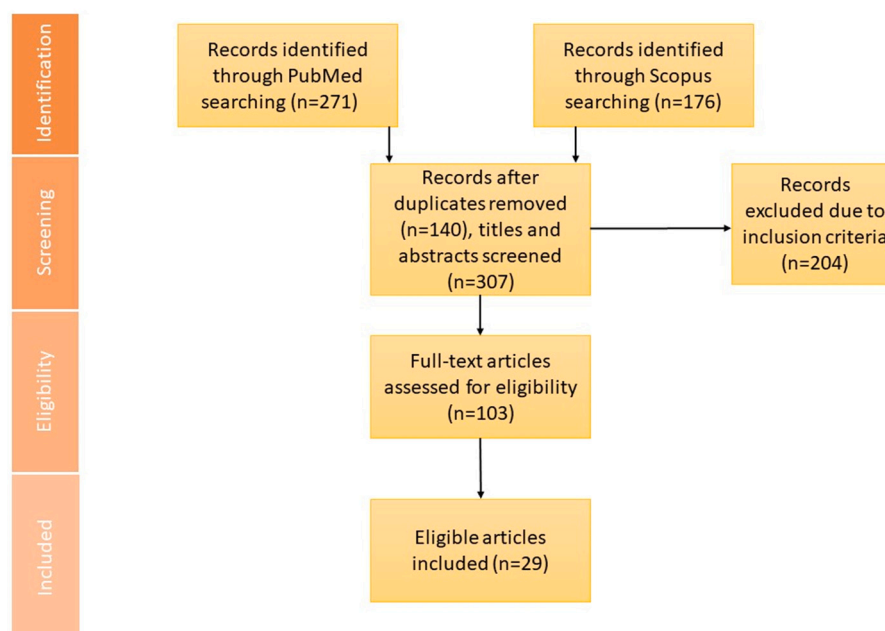


Fig. 1. PRISMA chart. On the basis of our search strategy, we found 447 records from PubMed (271) and Scopus (176). After removing duplicates and eligibility screening, 29 articles identified to be included in our systemic review.

Reporting Items for Systematic Reviews and Meta-Analyses (PRISMA) (Fig. 1) guideline [32]. We searched PubMed and Scopus until April 14, 2022. Details of search strategies are provided in supplementary data. The literature search was carried out separately by two reviewers to find studies that reported AIS post COVID-19 vaccination. Case reports, case series, original articles, editorial letters and short communications in English were collected. After removing duplicates, title and abstract screening was performed. The reference lists of included articles were analyzed to identify relevant studies. Collected data from articles was entered into Microsoft Excel.

3. Results and discussion

We found 447 articles after searching PubMed and Scopus until April 14, 2022 (Fig. 1). From those, 140 duplicates were removed. After excluding irrelevant articles, 29 studies (43 patients) were identified including 31 patients (72.1%) with viral vector vaccines, 8 patients (18.6%) after mRNA vaccines and 4 patients (9.3%) after whole inactivated virus vaccines.

3.1. Viral vector vaccine

Two types of viral vector vaccines including Vaxzevria (ChAdOx1 nCov-19) and Janssen COVID-19 Vaccine (Ad26.COVS-2) have been developed and administered globally [33]. We found just one report indicating AIS post Ad26.COVS-2 vaccination, but ChAdOx1 nCov-19 was the most common vaccine (30 cases, 69.7%) associated with AIS. ChAdOx1 nCov-19 vaccine has about 64.1% efficacy against severe SARS-CoV-2 infection after the first dose and 70.4% after two doses [34,35]. The Oxford COVID-19 Vaccine Trial Group performed a phase 1–2 trial to assess the safety, reactogenicity, and immunogenicity of ChAdOx1 nCov-19 vaccine and documented local and systemic reactions including pain at the injection site, fever, chills, asthenia, myalgia and headache [36]. There were no serious side effects associated with the administration of ChAdOx1-S in phase 1–2 trial [36]. Since the start of the large-scale vaccination program, a few rare adverse effects that could be associated with ChAdOx1 nCov-19 have been observed. GBS and vaccine-induced thrombotic thrombocytopenia (VITT), which can be accompanied by hemorrhages, have been reported

in several cases following ChAdOx1 nCov-19 injection [33]. Venous thrombosis in unusual locations such as the splanchnic venous circulation and cerebral venous sinus thrombosis (CVST) and also arterial thrombosis have been described in rare occasions [33].

Ad26.COVS-2 vaccine can be effective as much as 66.9% in preventing symptomatic SARS-CoV-2 infection after 14 days after injection. Also, 76.7% and 84.5% efficacy against severe-critical COVID-19 after 14 and 28 days following vaccination have been reported, respectively [37]. Although we found only one report of AIS post Ad26.COVS-2 vaccination, previous studies have shown several cases of VITT following Ad26.COVS-2 vaccination, some associated with CVST [38–40].

Table 1 illustrates reported cases of AIS following viral vector vaccination. We found 22 articles that describe 31 patients (30 with ChAdOx1 nCov-19 and 1 with Ad26.COVS-2). The majority of them (67.7%, 21 cases) had thrombocytopenia with positive anti-PF4 antibodies, indicating VITT diagnosis. From all of viral vector vaccine cases with AIS, 5 cases (16.1%) died within the hospital admission.

3.2. mRNA vaccine

The Moderna (mRNA-1273) and Pfizer-BioNTech (BNT162b2) are two types of mRNA COVID-19 vaccine with high efficacy (> 94%) [41,42]. Due to the short production time, scalability, safe administration, and potential to induce T-helper 1 (Th1) and T-helper 2 (Th2) responses, the mRNA-based vaccine technology represents as a rapidly widely available vaccine candidate and provides a viable alternative to the existing vaccines till now [43]. Their side effects are usually mild and transient [41,43], however rare cases of myocarditis and pericarditis have been reported post vaccination [44]. Moreover, several cases of venous and arterial thrombosis following mRNA vaccination have been reported [45,46], some associated with VITT [47,48]. Table 2 shows reported cases of AIS post mRNA vaccine injection. Five articles including 8 patients (7 BNT162b2 and 1 mRNA-1273) were identified in our search. Two of them had thrombocytopenia, out of those, one patient was positive for anti-PF4 antibodies. One case (12.5%) died during the hospital admission.

Table 1

Summary reports of acute ischemic stroke following the COVID-19 vaccination with viral vector vaccines.

Author(s)	No. of cases	Vaccine dose	Age gender	Past medical history/ medication(s)	Time from vaccination (days)	Clinical presentation	Imaging findings	Lab findings	Treatment/outcome
ChAdOx1 nCoV-19 M. A. Alammam [114]	1	First	43 male	obesity, hyperlipidemia	3	Right hemiparesis	Left paraventricular parietal infarct	Platelets count: NL	antiplatelets and statins therapy/alive
T. Al-Mayhani et al. [28]	3	N/A	* 35 female	N/A	11	headache, left hemiparesis, right gaze preference and drowsiness	occlusion of right MCA (M1 segment) + haemorrhagic transformation concurrent thrombosis: right portal vein thrombosis	thrombocytopenia, increased level of D-dimer, anti-PF4 antibodies: positive	decompressive hemicraniectomy, IVIG, fondaparinux and plasmapheresis/dead
		N/A	* 37 female	N/A	12	diffuse headache, left visual field loss, confusion and left arm weakness	left and right ICA occlusion concurrent thrombosis: CVST, PE, thrombosis of left jugular, right hepatic and both iliac veins	thrombocytopenia, increased level of D-dimer, anti-PF4 antibodies: positive	IVIG, methylprednisolone, plasmapheresis and fondaparinux/alive
		N/A	* 43 male	N/A	21	dysphasia	acute left frontal and insular infarct (MCA territory) + haemorrhagic transformation	thrombocytopenia, increased level of D-dimer, anti-PF4 antibodies: positive	platelet transfusion, IVIG, and fondaparinux/alive
S. A. Assiri et al. [80]	4	First	66 male	Cardiomyopathy, DM, HTN, dyslipidemia, IHD, prior stroke/ASA	10	Motor, sensory, vision, aphasia, dysphagia	Right MCA infarct	Platelets count: NL, increased level of D-dimer	rtPA/alive
		First	46 male	DM	7	Motor, sensory, Ataxia, dysarthria	Right MCA infarct	Platelets count: NL, increased level of D-dimer	ASA, Clopidogrel/alive
		First	56 male	DM, HTN, dyslipidemia, smoker	2	Ataxia, vertigo	Right lacunar thalamic stroke	Platelets count: NL, increased level of D-dimer	ASA/alive
		First	62 male	HTN, dyslipidemia, smoker	4	Motor, sensory, vision, dysarthria	Pontine infarction	Platelets count: NL, increased level of D-dimer	ASA, Clopidogrel/alive
A. Bayas et al. [115]	1	First	55 female	none	18	right-sided hemiparesis, and aphasia, conjunctival congestion retro-orbital pain binocular diplopia at vertical and right lateral gaze, right-sided focal seizures	left parietal lobe, and MCA territory infarct concurrent thrombosis: superior ophthalmic vein thrombosis (SOVT)	thrombocytopenia, anti-PF4 antibodies: negative	intravenous dexamethasone, levetiracetam, lacosamide, phenprocoumon/alive
G. Berlot et al. [116]	1	First	* 69 female	HTN, hysterectomy	9	headache, left hemiparesis	ICA and MCA occlusion, right hemispheric infarction concurrent thrombosis: descending aorta, celiac tripod, inferior mesenteric artery, and left pulmonary artery	thrombocytopenia, increased level of D-dimer, anti-PF4 reduced fibrinogen antibodies: positive	thromboaspiration, intravenous dexamethasone, IVIG, argatroban, mannitol, decompressive craniotomy/alive
R. A. Blauenfeldt et al. [117]	1	First	60 female	HTN and Hashimoto thyroiditis	9	headache, left hemiparesis and eye deviation to the right	Right MCA territory infarct	thrombocytopenia, increased level of D-dimer	hydrocortisone, dalteparin, platelet concentrates, hemicraniectomy/dead
N. Ceschia et al. [118]	1	First	* 73 female	hypercholesterolemia, HTN, positive family history for thrombophilia	14	no neurologic sign or symptom	Right PCA infarct Concurrent thrombosis: CVST, thrombosis in right medial gastrocnemius veins, pulmonary, left renal vein, right superficial femoral artery	thrombocytopenia, increased level of D-dimer, anti-PF4 antibodies: positive	IVIG, dexamethasone, fondaparinux and then warfarin, thromboendoarterectomy of right tibial artery, bivalirudin/alive
D. G. Corrêa et al. [119]	1	First	64 male	HTN	2	right superior and inferior limbs paresia	left nucleo-capsular infarct	Platelets count: NL	ASA/alive

(continued on next page)

Table 1 (continued)

Author(s)	No. of cases	Vaccine dose	Age gender	Past medical history/ medication(s)	Time from vaccination (days)	Clinical presentation	Imaging findings	Lab findings	Treatment/outcome
G. Costentin et al. [111]	1	First	* 26 female	None/ocp	8	headache, right hemiplegia and aphasia	Left MCA and M1 segment occlusion concurrent thrombosis: PE and portal vein thrombosis	thrombocytopenia, anti-PF4 antibodies: positive, decreased level of fibrinogen	mechanical thrombectomy/N/A
M. De Michele et al. [110]	2	First	* 57 female	mild hypothyroidism, treated breast cancer	9	left hemiplegia, right gaze deviation, dysarthria, and left neglect	first a Right MCA infarction and then a malignant infarct due to re-occlusion of MCA Concurrent thrombosis: thrombosis of splanchnic vein, pulmonary arteries	thrombocytopenia, increased level of D-dimer, anti-PF4 antibodies: positive	platelet transfusion, mechanical thrombectomy, betamethasone, decompressive craniectomy, IVIG, plasma exchange, fondaparinux/N/A
		First	* 55 female	mild hypothyroidism	10	transient aphasia and right hemiparesis, and then generalized seizures and coma	Right ICA and bilateral MCA infarct Concurrent thrombosis: thrombosis of portal vein, pulmonary arteries	thrombocytopenia, increased level of D-dimer, anti-PF4 antibodies: positive	IVIG, dexamethasone/dead
J. Kenda et al. [108]	1	First	* 51 female	hyperlipidemia	7	global aphasia, right sided hemiplegia and hemianopsia	occlusion of left M1 segment of MCA, minor ischemic changes in the left basal ganglia and insula + hemorrhagic transformation	thrombocytopenia, high level of D-dimer, anti-PF4 antibodies: positive	rtPA, mechanical thrombectomy, IVIG, fondaparinux and then ASA/alive
M. Mancuso et al. [29]	1	First	* 42 female	none	9	left hemiparesis	MCA and ACA occlusion, ischemia on the right middle temporal gyrus, insula and putamen + hemorrhagic transformation	thrombocytopenia, high level of D-dimer, anti-PF4 antibodies: positive	mechanical thrombectomy, intravenous dexamethasone, IVIG, fondaparinux, platelet infusion, decompressive hemicraniectomy/alive
M. Scully et al. [30]	2	First	* 39 female	none	10	N/A	MCA infarct	thrombocytopenia, high level of D-dimer, anti-PF4 antibodies: positive, increased level of fibrinogen	N/A/alive
		First	* 21 male	none	10	N/A	MCA infarct	thrombocytopenia, high level of D-dimer, anti-PF4 antibodies: positive, decreased level of fibrinogen	N/A/alive
A. Wills et al. [120]	1	N/A	* 42 female	smoker	14	left hemiplegia	Left CCA and right ICA infarct, then MCA and ACA infarcts	thrombocytopenia, anti-PF4 antibodies: positive	enoxaparin, heparin/dead
M. Garnier et al. [112]	1	N/A	* 26 female	N/A	8	Right hemiplegia, aphasia, headache, nausea	Left MCA infarction, concurrent thrombosis: PE, portal thrombosis extending to the splenomesenteric trunk and ileal veins	thrombocytopenia, anti-PF4 antibodies: positive, decreased level of fibrinogen	thrombectomy, corticosteroids, plasmatic exchange and anticoagulant/alive
A. Tiede [121]	2	First	* 61 female	N/A	9	Headache, dysarthria, left-sided hemiplegia, conjugated gaze palsy	Right MCA and ICA thrombosis, right MCA territory infarction + hemorrhagic transformation	thrombocytopenia, high level of D-dimer, anti-PF4 antibodies: positive	Argatroban, IVIG, dexamethasone/alive
		First	* 67 female	N/A	8	headache	Cortical infarctions, concurrent thrombosis: aortic arch thrombi	thrombocytopenia, high level of D-dimer, anti-PF4 antibodies: positive	Argatroban, IVIG, dexamethasone/alive
U. Walter et al. [122]	1	First	* 31 male	smoker	8	acute headache, aphasia, and right hemiparesis	Left MCA thrombosis and territory infarction Concurrent thrombosis:	Platelets count: NL, increased level of D-dimer, anti-PF4 antibodies: positive	rtPA, thrombectomy, ASA, danaparoid and then phenprocoumon/alive

(continued on next page)

Table 1 (continued)

Author(s)	No. of cases	Vaccine dose	Age gender	Past medical history/ medication(s)	Time from vaccination (days)	Clinical presentation	Imaging findings	Lab findings	Treatment/outcome
K. Y. Park et al. [31]	1	N/A	* 69 female	CAD, hyperlipidemia/ASA, rivaroxaban	13	dysarthria	parietal solid thrombus in the left carotid bulb small infarctions both MCA territories	thrombocytopenia, increased level of D-dimer, anti-PF4 antibodies: positive	Rivaroxaban/alive
M. George et al. [123]	1	N/A	71 male	N/A	3	Seizures	left Temporoparietal Cortex infarct	increased D-dimer	Antiplatelets, Antiepileptics/N/A
E. Pang et al. [124]	1	First	* 51 female	DM, obesity, nephrectomy	13	headache, Asymmetric (right >left) quadriplegia and aphasia	ICA thrombosis, left hemispheric internal watershed infarcts Concurrent thrombosis: CVST basilar thrombosis, infarction of right occipito-temporal, superior cerebellar, thalamic and internal capsula regions, pons, and mesencephalon. Concurrent thrombosis: left portal branch and right suprahepatic vein, aortic arch floating thrombus	thrombocytopenia, increased level of D-dimer, anti-PF4 antibodies: positive	mechanical thrombectomy, IVIG, fondaparinux and then bivalirudin, methylprednisolone/alive
V. D'Agostino et al. [125]	1	N/A	54 female	Meniere's disease	12	Left side signs, GCS 13	Concurrent thrombosis: left portal branch and right suprahepatic vein, aortic arch floating thrombus Right MCA infarction + hemorrhagic transformation Concurrent thrombosis: right internal carotid artery, CVST, right internal jugular vein, hepatic vein, and distal lower-limb vein; PE	thrombocytopenia, increased level of D-dimer, anti-PF4 antibodies: positive	N/A/Dead
A. Bourguignon et al. [126]	1	N/A	*69 male	DM, HTN, Obstructive Sleep Apnea, prostate cancer	12	Headache, confusion and left hemiplegia	Right MCA infarction + hemorrhagic transformation Concurrent thrombosis: right internal carotid artery, CVST, right internal jugular vein, hepatic vein, and distal lower-limb vein; PE	thrombocytopenia, increased level of D-dimer, anti-PF4 antibodies: positive	Fondaparinux, IVIG, rivaroxaban, plasma exchange/alive
Ad26.COV2-S A. Charidimou et al. [127]	1	N/A	* 37 female	Migraine/ocp	10	headache, left hemiparesis, hemineglect and right gaze deviation	occlusion of Right ICA, M1 segment of right MCA and ACA, acute right MCA infarct + hemorrhagic transformation. Concurrent thrombosis: left brachial vein and bilateral cephalic vein, right common femoral vein	thrombocytopenia, increased level of D-dimer, anti-PF4 antibodies: positive	mechanical thrombectomy, intravenous dexamethasone, IVIG, argatroban, decompressive hemicraniectomy/N/A

NL: normal; N/A: not available; anti-PF4 antibody: anti-platelet factor 4 antibody; IVIg: intravenous immunoglobulin; CVST: cerebral venous sinus thrombosis; MCA: middle cerebral artery; ICA: internal carotid artery; DM: diabetes mellitus; HTN: hypertension; IHD: ischemic heart disease; CAD: coronary artery disease; rtPA: recombinant tissue plasminogen activator; ASA: acetylsalicylic acid (aspirin); PCA: posterior cerebral artery; PE: Pulmonary Thrombosis.

* VITT Case.

Table 2

Summary reports of acute ischemic stroke following the COVID-19 vaccination with mRNA vaccines.

Author(s)	No. of cases	Vaccine dose	Age gender	Past medical history/ medication(s)	Time from vaccination (days)	Clinical presentation	Imaging findings	Lab findings	Treatment/Outcome
BNT 162b2									
S. A. Assiri et al. [80]	4	First	59 male	HTN, DM, dyslipidemia, smoker/clopidogrel	12	Sensory, Ataxia, Vertigo affection. Aphasia, dysphagia, dysarthria	PICA infarct	Platelets count: NL, increased level of D-dimer	ASA/alive
		Second	59 male	Dyslipidemia, hypercholesterolemia, smoker/ASA	23	Motor, Sensory, dysphagia, dysarthria	Right MCA thrombosis and infarction	Platelets count: NL, increased level of D-dimer	Thrombectomy/alive
		Second	80 female	Peripheral vascular neuropathy, dyslipidemia/ warfarin	7	Motor, Sensory, Vision, Aphasia and dysphagia, dysarthria	Left MCA infarction, Left Internal Carotid Artery occlusion	Platelets count: NL, increased level of D-dimer	Thrombectomy/alive
		First	36 female	Asthmatic, hypercholesterolemia	6	Motor, Sensory, Aphasia and dysphagia	Left MCA thrombosis and infarction	Platelets count: NL, increased level of D-dimer	Thrombectomy/alive
G. Famularo [81]	1	Second	87 female	ischemic heart disease, HTN, and hyperlipidemia/ ASA	1	dysarthria, right gaze deviation, and complete left hemiplegia	Right MCA occlusion	Platelets count: NL	Clopidogrel/alive
R. Giovane et al. [128]	1	First	62 male	HTN, DM, hyperlipidemia, ESRD,	1	left facial paralysis, dysarthria, slurred speech, anisocoria, left lower limb hemiballismus, left upper limb paralysis, horizontal nystagmus	bilateral thalamic infarction	thrombocytopenia, normal level of D-dimer, anti-PF4 antibodies: negative	ASA, Clopidogrel/alive
K. Yoshida et al. [129]	1	First	83 female	AF/rivaroxaban	3 (for both doses)	first stroke: right hemiplegia and motor aphasia, second stroke: left hemiplegia and left hemispatial neglect	first stroke: left insular cortex and corona radiata (occlusion of M1 segment of left MCA), second stroke: the right insular cortex, caudate, and corona radiata (occlusion of M1 segment of right MCA) then ischemic area spread to entire right MCA area	Platelets count: NL, increased level of D-dimer	first stroke: rtPA, mechanical thrombectomy, edoxaban,, second stroke: mechanical thrombectomy/N/A
mRNA-1273									
P.-H. Su et al. [48]	1	First	* 70 male	AF, COPD, HTN, Pancreatic cancer/ rivaroxaban	7	left side weakness	scattered infarcts at the right thalamus, parietal cortex, medial temporal, parietal-occipital lobe, left centrum semiovale and posterior cerebral artery territory	thrombocytopenia, increased level of D-dimer, decreased level of fibrinogen, anti-PF4 antibodies: positive	intravenous dexamethasone, IVIG, plasma exchange/dead

NL: normal; N/A: not available; anti-PF4 antibody: anti-platelet factor 4 antibody; IVIg: intravenous immunoglobulin; CVST: cerebral venous sinus thrombosis; MCA: middle cerebral artery; ICA: internal carotid artery; DM: diabetes mellitus; HTN: hypertension; IHD: ischemic heart disease; CAD: coronary artery disease; rtPA: recombinant tissue plasminogen activator; ASA: acetylsalicylic acid (aspirin); PICA: posterior inferior cerebellar artery; COPD: chronic obstructive pulmonary disease; AF: atrial fibrillation; ESRD: end-stage renal disease.

* VITT Case.

Table 3
Summary reports of acute ischemic stroke following the COVID-19 vaccination with whole inactivated virus vaccines.

Author(s)	No. of cases	vaccine dose	Age gender	Past medical history/medication(s)	Time from vaccination (days)	Clinical presentation	Imaging findings	Lab findings	Treatment/outcome
BBIP (Sinopharm) G. Elaidouni et al. [60]	1	First	36 male	HTN, DM, dyslipidemia, smoker/clopidogrel	2	headaches, left hemiparesis, left facial paralysis, left hemibody hypotonia, impaired consciousness	superficial and deep right parietal infarction	Platelets count and D-dimer: NL	ASA, Enoxaparine/alive
Sinovac R. Hidayat et al. [61]	3	First	77 male	CAD, DM, HTN, ischemic stroke	0	left lower limb hemiparesis, slurred speech	several infarctions in bilateral centrum semiovale, cortical-subcortical right frontal and temporal lobe, bilateral external capsule, and right pons lacunar infarcts in right frontoparietal region	Platelets count: NL	ASA, Clopidogrel/alive
		First	79 male	HTN, hypercholesterolemia, ex-smoker	2	left hemiparesis		Platelets count: NL	ASA/alive
		First	62 male	HTN, ischemic stroke	1	left hemiparesis, slurred speech, and facial asymmetry	watershed infarctions in right centrum semiovale and corona radiata	Platelets count: NL, normal D-dimer	ASA, Clopidogrel/alive

NL: normal; N/A: not available; DM: diabetes mellitus; HTN: hypertension; CAD: coronary artery disease; ASA: acetylsalicylic acid (aspirin).

3.3. Whole inactivated virus vaccine

CoronaVac (Sinovac) and BBIP-CorV (Sinopharm), as whole inactivated virus vaccines, have been used widely around the world [49,50]. Multiple clinical trials have been conducted to evaluate CoronaVac and BBIP-CorV efficacies but diverse results have been reported, probably due to different trial designs [51–54]. World health organization (WHO) indicates that CoronaVac has 51% efficacy against symptomatic SARS-CoV-2 infection and 100% efficacy against severe disease and hospitalization [55]. Moreover, efficacies of BBIP-CorV against symptomatic infection and hospitalization were both 79%, according to WHO [56]. Although common side effects of these two vaccines are mild to moderate [57,58], there are rare cases of thrombotic events [59–62]. As presented in Table 3, we found 2 articles including 4 patients (3 CoronaVac and 1 BBIP-CorV) with AIS after inactivated virus vaccine administration. None of them had thrombocytopenia, increased D-dimer or positive for anti-PF4 antibodies. No mortality was reported during the hospital course.

3.4. Background and clinical picture of reported cases of ischemic stroke

From all cases, 22 patients (51.1%) had VITT. Except for one case vaccinated with mRNA-1273, all of them had received viral vector vaccines.

Although there was not much difference between the number of male and female patients from all included studies (44% male and 56% female), the majority of cases with possible or definite VITT diagnosis were female (17 cases, 77.2%). Sixty-eight percent (15 cases) of the VITT cases are aged below 60 years. These findings are consistent with the previous studies that reported the risk of VITT appears to be greater in younger females under 60 [63,64].

The most common cardiovascular risk factors were hypertension (16 cases, 37.2%) and hyperlipidemia (11 cases, 25.5%). Two of the VITT cases who received viral vector vaccines have a history of oral contraceptive use. Interestingly, 9 patients (21%) who were taking antiplatelets or anticoagulants were among AIS patients (5 anti-platelets, 3 anticoagulants, 1 taking both). Neurological symptoms occurred suddenly within few hours to 23 days after vaccine administration. The most common symptoms were as follows [65]: hemiparesis or hemiparesis (26 cases, 60.4%), dysphasia (13 cases, 30.2%), dysarthria (12 cases, 28%) and headache (13 cases, 30.2%). Among 43 patients with AIS, at least 6 patients (14%) died during hospital admission.

Fourteen patients (32.5%) had additional thrombosis in other sites. Four of them (0.09%) showed concurrent CVST and ischemic stroke. CVST, portal vein thrombosis, pulmonary embolism, and thrombosis of jugular vein, hepatic vein, iliac veins, ophthalmic vein, medial gastrocnemius veins, renal vein, superficial femoral artery, carotid bulb, aortic arch, descending aorta, celiac tripod, inferior mesenteric artery and splanchnic vein were reported. All the patients with thrombosis in other sites were vaccinated with viral vector vaccines.

Hemorrhagic transformation following AIS occurred in 7 patients (16.27%).

3.5. Pathophysiology

The pathophysiology of VITT has not been totally understood yet. VITT, in terms of clinical manifestations, is very similar to autoimmune heparin-induced thrombocytopenia (HIT). HIT is an immune-mediated disorder induced by immunoglobulin G (IgG) antibodies against platelet factor 4 (PF4) complexed with heparin. This combination subsequently attaches to platelet FcRIIA receptors, activating platelets and causing platelet microparticle production [66]. These microparticles induce thrombocytopenia by generating blood clots and triggering a prothrombotic cascade, that lowers platelet count. Furthermore, the reticuloendothelial system, especially the spleen, eliminates antibody-coated platelets, aggravating thrombocytopenia [8,66–68]. It has also

been shown that certain individuals with clinical symptoms and biochemical markers suggestive of HIT surprisingly have not been exposed to heparin earlier. Antibodies in these individuals' sera aggressively activate platelets even in the lack of heparin. The majority of the reported spontaneous HIT cases had previously undergone orthopedic surgery (released glycosaminoglycans or RNA from knee cartilage due to tourniquet-related cell injury) or had infections (microorganism exposure) [69]. High level of anti-PF4-polyanion antibodies, as a platelet activator, is a common finding in both VITT and HIT [63]. However, the presence of these antibodies is neither a guarantee nor a prediction of VITT. Six individuals with anti-PF4-polyanion antibodies were detected in a Norwegian trial of 492 health care professionals who got one dose of ChAdOx1 nCov-19 vaccine, though these antibodies did not exhibit platelet-activating capabilities, and VITT did not occur in any of them [70]. Furthermore, anti-PF4-polyanion antibodies have not been found in suspected patients of VITT in another study [71]. Thus, it is likely that VITT pathogenesis is mediated by a number of distinct pathways.

Various possible pathways have been suggested for VITT involving platelets and PF4 thus far [72]. It's worth noting that the etiology of VITT may not be the same in every case. Thus, diverse processes should be thoroughly analyzed and investigated. One theory proposes that platelets interact directly with SARS-CoV-2 spike proteins generated after immunization. Spike proteins might have been overexpressed and released into the circulation in rare cases, interacting with platelets and causing platelet activation, PF4 releasing, and anti-PF4 antibody production, ultimately leading to thrombosis and thrombocytopenia [73].

Interactions between PF4 and particular COVID-19 vaccine components are another mechanism that has been suggested. Negatively charged double-stranded DNA and single-stranded mRNA can create extremely immunogenic complexes with PF4 just like heparin [73,74]. Due to microtrauma and micro bleeding at the injection site, double-stranded DNA carried by adenoviral vector-based COVID-19 vaccines, like ChAdOx1 nCov-19, can directly interact with PF4, leading to the generation of anti-PF4-polyanion antibodies which can stimulate platelets and end up causing thrombosis and thrombocytopenia [72]. A similar mechanism is probable for mRNA vaccines; however, due to changes that reduce pathogen-associated molecular pattern sensing mechanisms, such as replacement of uridine with N1-methyl-pseudouridine (m1P) [75], the immunogenic risk might be lowered leading to reduced rates of VITT seen with mRNA vaccines.

Patients with SARS-CoV-2 infection experience an elevated risk of thrombotic events such as AIS, due to severe inflammation reaction and subsequent hypercoagulable state [76]. Although the exact mechanism of AIS following COVID-19 vaccination is unknown, there is a chance that it is associated with COVID-19 vaccine-induced inflammation, similar to what has been shown with SARS-CoV-2 viral infection, leading to disseminated intravascular coagulation (DIC) and vascular endothelial dysfunction which eventually might induce large-vessel stroke [77–81]. This mechanism might play a major role particularly in patients with atherosclerotic lesions [81].

3.6. Evaluation and management

During the pandemic era, practitioners should ask AIS patients about history of COVID-19 vaccinations, within the last 1 month prior to the incident. In the case of positive vaccination history, in particular with viral vector vaccines, VITT evaluation is needed. The following items should be evaluated [72]:

- Complete blood cell count including platelet count
- Prothrombin time (PT)/activated partial thromboplastin time (APTT)
- D-dimer test
- Fibrinogen test

- PF4-heparin enzyme-linked immunosorbent assay (ELISA)

Platelet count below $150 \times 10^9/L$ [82], abnormal PT or APTT [83], significant elevation of D-dimer [83,84], low levels of fibrinogen and positive anti-PF4 antibodies [82–85] suggest VITT diagnosis.

Patients with possible or definite VITT should undergo imaging to find thrombosis in other probable sites, in particular dural sinuses and splanchnic veins [63,83]. It is suggested to admit the patients to the hospital and start non-heparin anticoagulants in case thrombosis is detected. Transfusions of platelets must be avoided [64,82,84]. Similar to the management of autoimmune HIT, administration of standard heparin or low-molecular weight heparin should be avoided. Alternative anticoagulants such as fondaparinux, danaparoid, argatroban, bivalirudin, rivaroxaban or apixaban can be used [86]. High-dose intravenous immune globulin (IVIG) treatment has been demonstrated to suppress antibody-mediated platelet activation, resulting in lower hypercoagulability and a fast rise in platelet count, and has been considered part of VITT therapy [87,88]. Plasma exchange is also recommended as a treatment option for people with refractory VITT. Anti-PF4 antibodies and increased inflammatory cytokines are removed by plasma exchange [89].

Patients who develop arterial or venous thrombosis and thrombocytopenia following receiving the ChAdOx1 nCov-19 vaccine s, should be advised not get a second dose [71,85,90].

Management of AIS associated with VITT or any kind of thrombocytopenia has not been well studied. Patients with substantial thrombocytopenia ($<100 \times 10^9/L$) have been generally excluded from AIS treatment with intravenous tissue-type plasminogen activator (IV tPA) clinical studies since it has been considered a relative contraindication [91]. IV tPA is the sole FDA-approved pharmacological therapy for AIS and its safety and efficacy have been studied in various settings [92–104]. Previous studies reported that the risk of symptomatic intracerebral hemorrhage (sICH) might be higher in AIS patients with severe thrombocytopenia who were treated with IV tPA, compared to those without thrombocytopenia [105,106]. Acute reperfusion therapy must be delivered to the AIS stroke patients as soon as possible and without any potential delays if there is no contraindication [107]. It's critical to cautiously use anticoagulants in AIS patients given the risk of hemorrhagic transformation, in case anticoagulant therapy is required for treatment of venous or arterial thrombosis. Hemorrhagic conversion of AIS might be fatal in individuals with low platelets and anticoagulation, particularly when platelet transfusion is not an option [108]. Mechanical thrombectomy with the current technology has been shown to significantly increase the recanalization rate and improve clinical outcomes in AIS with intracranial large vessel occlusion (LVO) [109]. Safety of this treatment has been studied in small case series of AIS patients with thrombocytopenia. Seven cases of AIS with LVO who have thrombocytopenia underwent mechanical thrombectomy successfully and safely among our studied patients, 6 of them did not receive IV tPA prior to thrombectomy [29,108,110–112]. Cascio Rizzo et al. also indicated that despite that re-occlusion after revascularization may happen due to the hypercoagulable state, mechanical thrombectomy is a feasible and safe treatment in patients with VITT and AIS [113]. It is suggested not to use intravenous heparin throughout the thrombectomy procedure in these patients [108].

4. Conclusion

The association between AIS and prior COVID-19 vaccination is still unclear, particularly in the absence of VITT. A group of the patients studied in this systematic review have established cardiovascular risk factors and well-known underlying mechanisms such as atrial fibrillation and it is not clear if COVID-19 had any role in the development of AIS.

We suggest that health care providers taking care of stroke patients

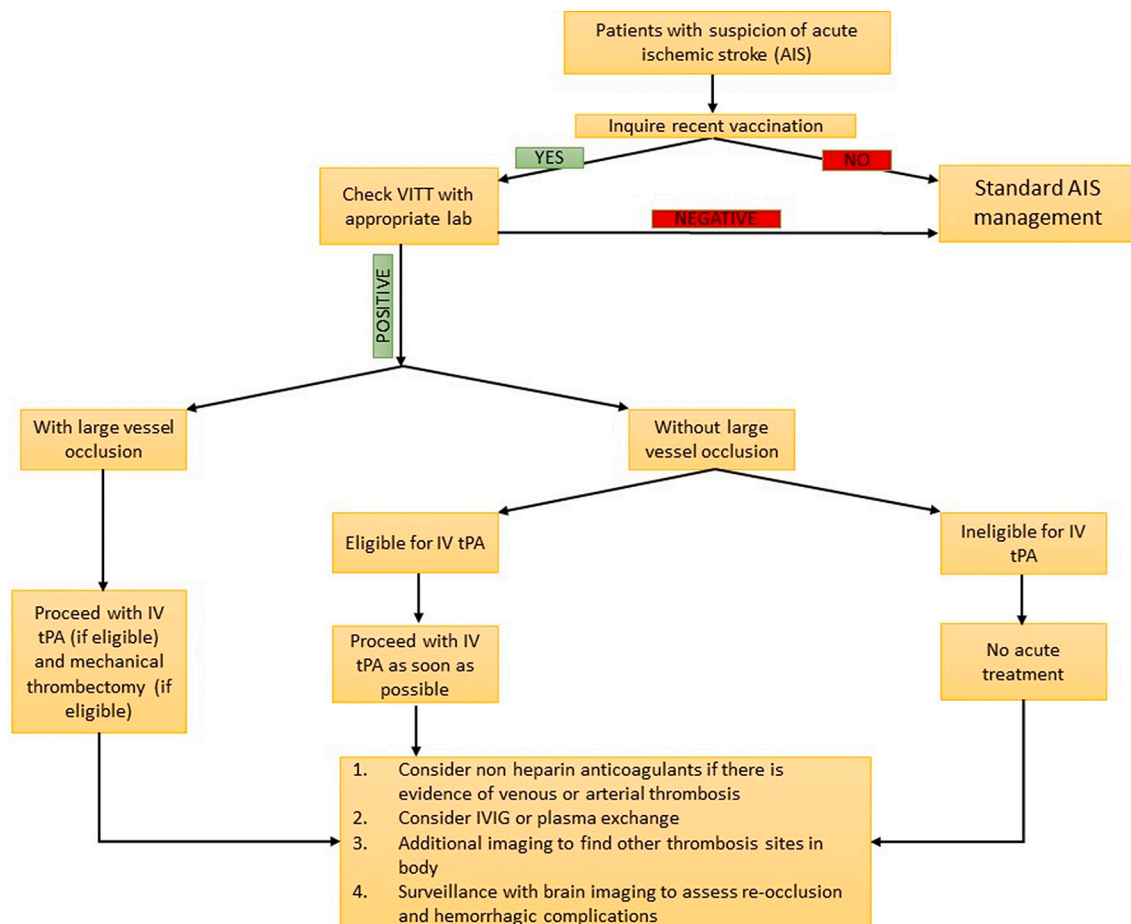


Fig. 2. Treatment algorithm.

inquire about history of COVID-19 vaccination, particularly within 1 month prior to the incident, order the appropriate blood tests and brain imaging and apply the treatment algorithm outlined in Fig. 2.

Of note, the benefits of COVID-19 vaccination remarkably outweigh the very small risk of AIS, CVST and other thrombotic events. Thus, the public must be reassured that vaccination is the most effective strategy to stop COVID-19 pandemic.

Data availability

The data that support the findings of this study are available from the corresponding author upon reasonable request.

Funding

This research did not receive any specific grant from funding agencies in the public, commercial, or not-for-profit sectors.

Declarations of interest

The authors report no relevant conflict of interest.

Appendix A. Supplementary data

Supplementary data to this article can be found online at <https://doi.org/10.1016/j.jns.2022.120327>.

References

- [1] N. Rezaei, S. Ashkevarian, M.K. Fathi, S. Hanaei, Z. Kolahchi, S.S. Ladi Seyedian, et al., Introduction on coronavirus disease (COVID-19) pandemic: the global challenge, *Adv. Exp. Med. Biol.* 1318 (2021) 1–22.
- [2] Z. Kolahchi, M. De Domenico, L.Q. Uddin, V. Cauda, I. Grossmann, L. Lacasa, et al., COVID-19 and its global economic impact, *Adv. Exp. Med. Biol.* 1318 (2021) 825–837.
- [3] A. Mowla, Stroke care during the COVID-19 pandemic; a global challenge, *Iran J. Med. Sci.* 45 (5) (2020) 323–324.
- [4] N.G. Kounis, I. Koniari, C. de Gregorio, D. Velissaris, K. Petalas, A. Brinia, et al., Allergic reactions to current available COVID-19 vaccinations: pathophysiology, causality, and therapeutic considerations, *Vaccines (Basel)* 9 (3) (2021).
- [5] M. Sharifian-Dorche, M. Bahmanyar, A. Sharifian-Dorche, P. Mohammadi, M. Nomovi, A. Mowla, Vaccine-induced immune thrombotic thrombocytopenia and cerebral venous sinus thrombosis post COVID-19 vaccination; a systematic review, *J. Neurol. Sci.* 428 (2021), 117607.
- [6] S. Kreps, S. Prasad, J.S. Brownstein, Y. Hswen, B.T. Garibaldi, B. Zhang, et al., Factors associated with US adults' likelihood of accepting COVID-19 vaccination, *JAMA Netw. Open* 3 (10) (2020), e2025594.
- [7] K. Pogue, J.L. Jensen, C.K. Stancil, D.G. Ferguson, S.J. Hughes, E.J. Mello, et al., Influences on attitudes regarding potential COVID-19 vaccination in the United States, *Vaccines (Basel)* 8 (4) (2020).
- [8] A.F. Hernández, D. Calina, K. Poulas, A.O. Docea, A.M. Tsatsakis, Safety of COVID-19 vaccines administered in the EU: should we be concerned? *Toxicol. Rep.* 8 (2021) 871–879.
- [9] H.A. Mushtaq, A. Khedr, T. Koritala, B.N. Bartlett, N.K. Jain, S.A. Khan, A review of adverse effects of COVID-19 vaccines, *Infez Med.* 30 (1) (2022) 1–10.
- [10] M. Poursadeghfar, M. Sharifian-Dorche, A. Nemat, A. Mowla, Simultaneous encephalitis and neuroretinitis after COVID-19 in a young adult: a case report, *J. Neurol. Res.* 11 (5) (2021) 102–107.
- [11] P. Jabbour, A.A. Dmytriw, A. Sweid, M. Pletin, K. Bekelis, N. Sourour, et al., Characteristics of a COVID-19 cohort with large vessel occlusion: a multicenter international study, *Neurosurgery* 90 (6) (2022) 725–733.
- [12] A.A. Dmytriw, M. Dibas, K. Phan, A. Efendizade, J. Ospel, C. Schirmer, et al., Acute ischaemic stroke associated with SARS-CoV-2 infection in North America, *J. Neurol. Neurosurg. Psychiatry* 93 (4) (2022) 360–368.

- [13] A.A. Dmytriw, M. Dibas, C.M. Schirmer, F. Settecase, M.K.S. Heran, A. Efendizade, et al., Age and acute ischemic stroke outcome in north American patients with COVID-19, *J. Am. Heart Assoc.* 10 (14) (2021), e21046.
- [14] H. Jafari Khaljiri, M. Jamalkhah, A. Amini Harandi, H. Pakdaman, M. Moradi, A. Mowla, Comprehensive review on neuro-COVID-19 pathophysiology and clinical consequences, *Neurotox. Res.* 39 (5) (2021) 1613–1629.
- [15] F. Vahabzad, M. Sharifian Dorche, P. Mohammadi, K. Khatibi, A. Mowla, COVID-19-related acute ischemic stroke in young adults: what is the optimal antithrombotic regimen for secondary prevention? *J. Neurol. Res.* 10 (5) (2020) 203–206.
- [16] S. Shahjouei, G. Tsvigoulis, G. Farahmand, E. Koza, A. Mowla, A. Vafaei Sadr, et al., SARS-CoV-2 and stroke characteristics: a report from the multinational COVID-19 stroke study group, *Stroke*. 52 (5) (2021) e117–e30.
- [17] S. Shahjouei, M. Anyaehie, E. Koza, G. Tsvigoulis, S. Naderi, A. Mowla, et al., SARS-CoV-2 is a culprit for some, but not all acute ischemic strokes: a report from the multinational COVID-19 stroke study group, *J. Clin. Med.* 10 (5) (2021).
- [18] V.R. Ostovan, R. Foroughi, M. Rostami, M. Almasi-Dooghace, M. Esmaili, A. A. Bidaki, et al., Cerebral venous sinus thrombosis associated with COVID-19: a case series and literature review, *J. Neurol.* 268 (10) (2021) 3549–3560.
- [19] A. Mowla, B. Shakibajhromi, S. Shahjouei, A. Borhani-Haghighi, N. Rahimian, H. Baharvahdat, et al., Cerebral venous sinus thrombosis associated with SARS-CoV-2: a multinational case series, *J. Neurol. Sci.* 419 (2020), 117183.
- [20] A. Mowla, S. Sizdahkhani, M. Sharifian-Dorche, P. Selvan, B.A. Emanuel, M. S. Tenser, et al., Unusual pattern of arterial macrothrombosis causing stroke in a young adult recovered from COVID-19, *J. Stroke Cerebrovasc. Dis.* 29 (12) (2020), 105353.
- [21] M. Sharifian-Dorche, P. Huot, M. Osheroov, D. Wen, A. Saveriano, P.S. Giacomini, et al., Neurological complications of coronavirus infection; a comparative review and lessons learned during the COVID-19 pandemic, *J. Neurol. Sci.* 417 (2020), 117085.
- [22] S. Shahjouei, S. Naderi, J. Li, A. Khan, D. Chaudhary, G. Farahmand, et al., Risk of stroke in hospitalized SARS-CoV-2 infected patients: a multinational study, *EBioMedicine*. 59 (2020), 102939.
- [23] A.A. Dmytriw, K. Phan, C. Schirmer, F. Settecase, M.K.S. Heran, A. Efendizade, et al., Ischaemic stroke associated with COVID-19 and racial outcome disparity in North America, *J. Neurol. Neurosurg. Psychiatry* 91 (12) (2020) 1362–1364.
- [24] B. Shakibajhromi, A. Borhani-Haghighi, S. Haseli, A. Mowla, Cerebral venous sinus thrombosis might be under-diagnosed in the COVID-19 era, *eNeurologicalSci.* 20 (2020) 100256.
- [25] A.A. Divani, S. Andalib, M. Di Napoli, S. Lattanzi, M.S. Hussain, J. Biller, et al., Coronavirus disease 2019 and stroke: clinical manifestations and pathophysiological insights, *J. Stroke Cerebrovasc. Dis.* 29 (8) (2020), 104941.
- [26] M. Kakovan, S. Ghorbani Shirkouhi, M. Zarei, S. Andalib, Stroke associated with COVID-19 vaccines, *J. Stroke Cerebrovasc. Dis.* 31 (6) (2022), 106440.
- [27] S. Aghabaklou, S.-M. Razavi, P. Mohammadi, S. Gholamin, A. Mowla, Cerebral coagulation complications following COVID-19 adenoviral vector vaccines: a systematic review, *J. Neurol. Res.* 11 (5) (2021) 69–76.
- [28] T. Al-Mayhany, S. Saber, M.J. Stubbs, N.A. Losseff, R.J. Perry, R.J. Simister, et al., Ischaemic stroke as a presenting feature of ChAdOx1 nCoV-19 vaccine-induced immune thrombotic thrombocytopenia, *J. Neurol. Neurosurg. Psychiatry* 92 (11) (2021) 1247–1248.
- [29] M. Mancuso, D.L. Lauretti, N. Cecconi, M. Santini, V. Lami, G. Orlandi, et al., Arterial intracranial thrombosis as the first manifestation of vaccine-induced immune thrombotic thrombocytopenia (VITT): a case report, *Neurol. Sci.* 43 (3) (2022) 2085–2089.
- [30] M. Scully, D. Singh, R. Lown, A. Poles, T. Solomon, M. Levi, et al., Pathologic antibodies to platelet factor 4 after ChAdOx1 nCoV-19 vaccination, *N. Engl. J. Med.* 384 (23) (2021) 2202–2211.
- [31] K.Y. Park, D.Y. Jeong, S.H. Ha, B.J. Kim, Arterial embolic infarction after COVID-19 vaccination associated with antiplatelet factor 4 antibody, *J. Clin. Neurol.* 18 (2) (2022) 230–232.
- [32] B. Hutton, G. Salanti, D.M. Caldwell, A. Chaimani, C.H. Schmid, C. Cameron, et al., The PRISMA extension statement for reporting of systematic reviews incorporating network meta-analyses of health care interventions: checklist and explanations, *Ann. Intern. Med.* 162 (11) (2015) 777–784.
- [33] P.P. Piccaluga, A. Di Guardo, A. Lagni, V. Lotti, E. Diani, M. Navari, et al., COVID-19 vaccine: between myth and truth, *Vaccines*. 10 (3) (2022) 349.
- [34] M.N. Ramasamy, A.M. Minassian, K.J. Ewer, A.L. Flaxman, P.M. Folegatti, D. R. Owens, et al., Safety and immunogenicity of ChAdOx1 nCoV-19 vaccine administered in a prime-boost regimen in young and old adults (COV002): a single-blind, randomised, controlled, phase 2/3 trial, *Lancet*. 396 (10267) (2021) 1979–1993.
- [35] M. Voysey, S.A.C. Clemens, S.A. Madhi, L.Y. Weckx, P.M. Folegatti, P.K. Aley, et al., Safety and efficacy of the ChAdOx1 nCoV-19 vaccine (AZD1222) against SARS-CoV-2: an interim analysis of four randomised controlled trials in Brazil, South Africa, and the UK, *Lancet*. 397 (10269) (2021) 99–111.
- [36] P.M. Folegatti, K.J. Ewer, P.K. Aley, B. Angus, S. Becker, S. Belij-Rammerstorfer, et al., Safety and immunogenicity of the ChAdOx1 nCoV-19 vaccine against SARS-CoV-2: a preliminary report of a phase 1/2, single-blind, randomised controlled trial, *Lancet*. 396 (10249) (2020) 467–478.
- [37] J. Sadoff, G. Gray, A. Vandebosch, V. Cárdenas, G. Shukarev, B. Grinsztejn, et al., Safety and efficacy of single-dose Ad26.COV2.S vaccine against Covid-19, *N. Engl. J. Med.* 384 (23) (2021) 2187–2201.
- [38] K.-L. Muir, A. Kallam, S.A. Koepsell, K. Gundabolu, Thrombotic thrombocytopenia after Ad26.COV2.S vaccination, *N. Engl. J. Med.* 384 (20) (2021) 1964–1965.
- [39] J. Sadoff, K. Davis, M. Douguilh, Thrombotic thrombocytopenia after Ad26.COV2.S vaccination — response from the manufacturer, *N. Engl. J. Med.* 384 (20) (2021) 1965–1966.
- [40] I. See, J.R. Su, A. Lale, E.J. Woo, A.Y. Guh, T.T. Shimabukuro, et al., US case reports of cerebral venous sinus thrombosis with thrombocytopenia after Ad26.COV2.S vaccination, march 2 to April 21, 2021, *JAMA*. 325 (24) (2021) 2448–2456.
- [41] L.R. Baden, H.M. El Sahly, B. Essink, K. Kotloff, S. Frey, R. Novak, et al., Efficacy and safety of the mRNA-1273 SARS-CoV-2 vaccine, *N. Engl. J. Med.* 384 (5) (2021) 403–416.
- [42] F.P. Polack, S.J. Thomas, N. Kitchin, J. Absalon, A. Gurtman, S. Lockhart, et al., Safety and efficacy of the BNT162b2 mRNA Covid-19 vaccine, *N. Engl. J. Med.* 383 (27) (2020) 2603–2615.
- [43] N. Pardi, M.J. Hogan, F.W. Porter, D. Weissman, mRNA vaccines - a new era in vaccinology, *Nat. Rev. Drug Discov.* 17 (4) (2018) 261–279.
- [44] CDC, Myocarditis and Pericarditis After mRNA COVID-19 Vaccination 2021 [updated 11/21/2021]. Available from: <https://www.cdc.gov/coronavirus/2019-ncov/vaccines/safety/myocarditis.html>.
- [45] T.-M. Tu, S.-J. Yi, J.S. Koh, S.E. Saffari, R.H.M. Hoe, G.J. Chen, et al., Incidence of cerebral venous thrombosis following SARS-CoV-2 infection vs mRNA SARS-CoV-2 vaccination in Singapore, *JAMA Netw. Open* 5 (3) (2022) e222940-e.
- [46] L. Dias, R. Soares-Dos-Reis, J. Meira, D. Ferrão, P.R. Soares, A. Pastor, et al., Cerebral venous thrombosis after BNT162b2 mRNA SARS-CoV-2 vaccine, *J. Stroke Cerebrovasc. Dis.* 30 (8) (2021), 105906.
- [47] S. Sangli, A. Virani, N. Cheronis, B. Vannatter, C. Minich, S. Noronha, et al., Thrombosis with thrombocytopenia after the messenger RNA-1273 vaccine, *Ann. Intern. Med.* 174 (10) (2021) 1480–1482.
- [48] P.-H. Su, Y.-C. Yu, W.-H. Chen, H.-C. Lin, Y.-T. Chen, M.-H. Cheng, et al., Case report: vaccine-induced immune thrombotic thrombocytopenia in a pancreatic Cancer patient after vaccination with messenger RNA–1273, *Fron. Med.* 8 (2021).
- [49] Team VGCVT, COVID19 Vaccine Tracker, Sinopharm (Beijing): Covilo 2022, Available from: <https://covid19.trackvaccines.org/vaccines/5/>.
- [50] Team VGCVT, COVID19 Vaccine Tracker, Sinovac: CoronaVac 2022, Available from: <https://covid19.trackvaccines.org/vaccines/7/>.
- [51] J. Belayachi, M. Obtel, R. Razine, R. Abouqal, Long term effectiveness of inactivated vaccine BBIBP-CorV (Vero Cells) against COVID-19 associated severe and critical hospitalization in Morocco, *medRxiv* (2022), <https://doi.org/10.1101/2022.01.25.22269822>.
- [52] Z. Vokó, Z. Kiss, G. Surján, O. Surján, Z. Barcza, B. Pályi, et al., Nationwide effectiveness of five SARS-CoV-2 vaccines in Hungary-the HUN-VE study, *Clin. Microbiol. Infect.* 28 (3) (2022) 398–404.
- [53] A. Jara, E.A. Undurraga, C. González, F. Paredes, T. Fontecilla, G. Jara, et al., Effectiveness of an inactivated SARS-CoV-2 vaccine in Chile, *N. Engl. J. Med.* 385 (10) (2021) 875–884.
- [54] M. Tanriover, L. Doganay, M. Akova, H. Güner, A. Azap, S. Akhan, et al., Efficacy and safety of an inactivated whole-virion SARS-CoV-2 vaccine (CoronaVac): interim results of a double-blind, randomised, placebo-controlled, phase 3 trial in Turkey, *Lancet* 398 (2021).
- [55] (WHO) WHO, The Sinovac-CoronaVac COVID-19 Vaccine: What You Need to Know 2022, Available from: <https://www.who.int/news-room/feature-stories/detail/the-sinovac-covid-19-vaccine-what-you-need-to-know>.
- [56] (WHO) WHO, The Sinopharm COVID-19 Vaccine: What You Need to Know 2022, Available from: <https://www.who.int/news-room/feature-stories/detail/the-sinopharm-covid-19-vaccine-what-you-need-to-know#:~:text=How%20efficacious%20is%20the%20vaccine,efficacy%20against%20hospitalization%20was%2079%25>.
- [57] Z. Wu, Y. Hu, M. Xu, Z. Chen, W. Yang, Z. Jiang, et al., Safety, tolerability, and immunogenicity of an inactivated SARS-CoV-2 vaccine (CoronaVac) in healthy adults aged 60 years and older: a randomised, double-blind, placebo-controlled, phase 1/2 clinical trial, *Lancet Infect. Dis.* 21 (6) (2021) 803–812.
- [58] S. Xia, Y. Zhang, Y. Wang, H. Wang, Y. Yang, G.F. Gao, et al., Safety and immunogenicity of an inactivated SARS-CoV-2 vaccine, BBIBP-CorV: a randomised, double-blind, placebo-controlled, phase 1/2 trial, *Lancet Infect. Dis.* 21 (1) (2021) 39–51.
- [59] M.G. Vallone, A.L. Falcón, H.M. Castro, A. Ferraris, R.F. Cantarella, M. I. Staneloni, et al., Thrombotic events following Covid-19 vaccines compared to influenza vaccines, *Eur. J. Int. Med.* 99 (2022) 82–88.
- [60] G. Elaidouni, Z. Chetouani, C.B. Manal Merbouh, H. Bkiyar, B. Housni, Acute ischemic stroke after first dose of inactivated COVID-19 vaccine: a case report, *Radiol. Case Rep.* 17 (6) (2022) 1942–1945.
- [61] R. Hidayat, D. Diafiri, R.A. Zairinal, G.R. Arifin, F. Azzahroh, N. Widjaya, et al., Acute Ischaemic stroke incidence after coronavirus vaccine in Indonesia: case series, *Curr. Neurovasc. Res.* 18 (3) (2021) 360–363.
- [62] S. Hameed, A.F. Khan, S. Khan, M. Wasay, First report of cerebral venous thrombosis following inactivated-virus Covid vaccination (Sinopharm and Sinovac), *J. Stroke Cerebrovasc. Dis.* 31 (3) (2022), 106298.
- [63] N.H. Schultz, I.H. Sørvoll, A.E. Michelsen, L.A. Munthe, F. Lund-Johansen, M. T. Ahlen, et al., Thrombosis and thrombocytopenia after ChAdOx1 nCoV-19 vaccination, *N. Engl. J. Med.* 384 (22) (2021) 2124–2130.
- [64] Geoffrey D. Barnes, Adam Cuker, Gregory Piazza, Deborah Siegal, Vaccine-induced Thrombotic Thrombocytopenia (VITT) and COVID-19 Vaccines: What Cardiovascular Clinicians Need to Know 2021, Available from: <https://www.acc.org/latest-in-cardiology/articles/2021/04/01/01/42/vaccine-induced-thrombotic-thrombocytopenia-vitt-and-covid-19-vaccines>.

- [65] K.S. Yew, E.M. Cheng, Diagnosis of acute stroke, *Am. Fam. Physician* 91 (8) (2015) 528–536.
- [66] C. Vayne, T.H. Nguyen, J. Rollin, N. Charuel, A. Poupon, C. Poupard, et al., Characterization of new monoclonal PF4-specific antibodies as useful tools for studies on typical and autoimmune heparin-induced thrombocytopenia, *Thromb. Haemost.* 121 (3) (2021) 322–331.
- [67] P.R. Mehta, S. Apap Mangion, M. Bengier, B.R. Stanton, J. Czuprynska, R. Arya, et al., Cerebral venous sinus thrombosis and thrombocytopenia after COVID-19 vaccination – a report of two UK cases, *Brain Behav. Immun.* 95 (2021) 514–517.
- [68] D.B. Cines, J.B. Bussel, SARS-CoV-2 vaccine-induced immune thrombotic thrombocytopenia, *N. Engl. J. Med.* 384 (23) (2021) 2254–2256.
- [69] A. Greinacher, K. Selleng, T.E. Warkentin, Autoimmune heparin-induced thrombocytopenia, *J. Thromb. Haemost.* 15 (11) (2017) 2099–2114.
- [70] I.H. Sørvoll, K.D. Horvei, S.L. Ernsten, L.J. Laegreid, S. Lund, R.H. Grønli, et al., An observational study to identify the prevalence of thrombocytopenia and anti-PF4/polyanion antibodies in Norwegian health care workers after COVID-19 vaccination, *J. Thromb. Haemost.* 19 (7) (2021) 1813–1818.
- [71] J. Douxfils, J. Favresse, J.M. Dogné, T. Lecompte, S. Susen, C. Cordonnier, et al., Hypotheses behind the very rare cases of thrombosis with thrombocytopenia syndrome after SARS-CoV-2 vaccination, *Thromb. Res.* 203 (2021) 163–171.
- [72] P.-W. Chen, Z.-Y. Tsai, T.-H. Chao, Y.-H. Li, C.-J.-Y. Hou, P.-Y. Liu, Addressing vaccine-induced immune thrombotic thrombocytopenia (VITT) following COVID-19 vaccination: a Mini-review of practical strategies, *Acta Cardiol. Sin.* 37 (4) (2021) 355–364.
- [73] P. Rzymiski, B. Perek, R. Flisiak, Thrombotic thrombocytopenia after COVID-19 vaccination: in search of the underlying mechanism, *Vaccines* 9 (6) (2021), 559.
- [74] D. McGonagle, G. De Marco, C. Bridgewood, Mechanisms of immunothrombosis in vaccine-induced thrombotic thrombocytopenia (VITT) compared to natural SARS-CoV-2 infection, *J. Autoimmun.* 121 (2021), 102662.
- [75] E. Bettini, M. Locci, SARS-CoV-2 mRNA vaccines: immunological mechanism and beyond, *Vaccines* (Basel). 9 (2) (2021).
- [76] A. Vogrig, G.L. Gigli, C. Bnà, M. Morassi, Stroke in patients with COVID-19: clinical and neuroimaging characteristics, *Neurosci. Lett.* 743 (2021) 135564.
- [77] M.T. Heneka, D. Golenbock, E. Latz, D. Morgan, R. Brown, Immediate and long-term consequences of COVID-19 infections for the development of neurological disease, *Alzheimers Res. Ther.* 12 (1) (2020) 69.
- [78] F. Zhou, T. Yu, R. Du, G. Fan, Y. Liu, Z. Liu, et al., Clinical course and risk factors for mortality of adult inpatients with COVID-19 in Wuhan, China: a retrospective cohort study, *Lancet.* 395 (10229) (2020) 1054–1062.
- [79] E. Gonçalves de Andrade, E. Šimončičová, M. Carrier, H.A. Vecchiarelli, M.-È. Robert, M.-È. Tremblay, Microglia fighting for neurological and mental health: on the central nervous system frontline of COVID-19 pandemic, *Front. Cell. Neurosci.* 15 (2021).
- [80] S.A. Assiri, R.M.M. Althaqafi, K. Alswat, A.A. Alghamdi, N.E. Alomairi, D. M. Nemenqani, et al., Post COVID-19 vaccination-associated neurological complications, *Neuropsychiatr. Dis. Treat.* 18 (2022) 137–154.
- [81] G. Famularo, Stroke after COVID-19 vaccination, *Acta Neurol. Scand.* 145 (6) (2022) 787–788.
- [82] Diagnostic and treatment recommendations from the FACME ad-hoc expert working group on the management of cerebral venous sinus thrombosis associated with COVID-19 vaccination, *Neurologia* 36 (6) (2021) 451–461.
- [83] I. Nazy, U.J. Sachs, D.M. Arnold, S.E. McKenzie, P. Choi, K. Althaus, et al., Recommendations for the clinical and laboratory diagnosis of VITT against COVID-19: communication from the ISTH SSC subcommittee on platelet immunology, *J. Thromb. Haemost.* 19 (6) (2021) 1585–1588.
- [84] K.L. Furie, M. Cushman, M.S.V. Elkind, P.D. Lyden, G. Saposnik, Diagnosis and management of cerebral venous sinus thrombosis with vaccine-induced immune thrombotic thrombocytopenia, *Stroke* 52 (7) (2021) 2478–2482.
- [85] M. Sholzberg, D.M. Arnold, A. Laupacis, Recognizing, managing and reporting vaccine-induced immune thrombotic thrombocytopenia, *Can. Med. Assoc. J.* 193 (24) (2021) E913.
- [86] M. Hogan, J.S. Berger, Heparin-induced thrombocytopenia (HIT): review of incidence, diagnosis, and management, *Vasc. Med.* 25 (2) (2020) 160–173.
- [87] D. Tsilingiris, N.G. Vallianou, I. Karampela, M. Dalamaga, Vaccine induced thrombotic thrombocytopenia: the shady chapter of a success story, *Metabol. Open* 11 (2021), 100101.
- [88] G.M. Arepally, T.L. Ortel, Vaccine-induced immune thrombotic thrombocytopenia: what we know and do not know, *Blood* 138 (4) (2021) 293–298.
- [89] C.J. Patriquin, V. Laroche, R. Selby, J. Pendergrast, D. Barth, B. Côté, et al., Therapeutic plasma exchange in vaccine-induced immune thrombotic thrombocytopenia, *N. Engl. J. Med.* 385 (9) (2021) 857–859.
- [90] D.M. Smadja, Q.Y. Yue, R. Chocron, O. Sanchez, Louet A. Lillo-Le, Vaccination against COVID-19: insight from arterial and venous thrombosis occurrence using data from VigilBase, *Eur. Respir. J.* 58 (1) (2021).
- [91] W.J. Powers, A.A. Rabinstein, T. Ackerson, O.M. Adeoye, N.C. Bambakidis, K. Becker, et al., 2018 guidelines for the early management of patients with acute ischemic stroke: a guideline for healthcare professionals from the American Heart Association/American Stroke Association, *Stroke* 49 (3) (2018) e46–e99.
- [92] A. Mowla, B. Shakibajahromi, A. Arora, A. Seifi, R.N. Sawyer, P. Shirani, Thrombolysis for stroke in elderly in the late window period, *Acta Neurol. Scand.* 144 (6) (2021) 663–668.
- [93] A. Mowla, M. Sharifian-Dorche, S. Mehla, N.S. Lail, A. Sharifian-Dorche, C. B. Vaughn, et al., Safety and efficacy of antiplatelet use before intravenous thrombolysis for acute ischemic stroke, *J. Neurol. Sci.* 425 (2021), 117451.
- [94] A. Mowla, A. Memon, S.M. Razavi, N.S. Lail, C.B. Vaughn, P. Mohammadi, et al., Safety of intravenous thrombolysis for acute ischemic stroke in patients taking warfarin with subtherapeutic INR, *J. Stroke Cerebrovasc. Dis.* 30 (5) (2021), 105678.
- [95] H. Kamal, B.K. Mehta, M.K. Ahmed, K.S. Kavak, A. Zha, N.S. Lail, et al., Laboratory factors associated with symptomatic hemorrhagic conversion of acute stroke after systemic thrombolysis, *J. Neurol. Sci.* 420 (2021), 117265.
- [96] A. Mowla, H. Shah, N.S. Lail, C.B. Vaughn, P. Shirani, R.N. Sawyer, Statins use and outcome of acute ischemic stroke patients after systemic thrombolysis, *Cerebrovasc. Dis.* 49 (5) (2020) 503–508.
- [97] S. Shahjouei, G. Tsivgoulis, N. Goyal, A. Sadighi, A. Mowla, M. Wang, et al., Safety of intravenous thrombolysis among patients taking direct Oral anticoagulants: a systematic review and Meta-analysis, *Stroke* 51 (2) (2020) 533–541.
- [98] A. Mowla, H. Kamal, N.S. Lail, C. Vaughn, P. Shirani, S. Mehla, et al., Intravenous thrombolysis for acute ischemic stroke in patients with thrombocytopenia, *J. Stroke Cerebrovasc. Dis.* 26 (7) (2017) 1414–1418.
- [99] M.A. AbdelRazek, A. Mowla, D. Hohnacki, W. Zimmer, R. Elsayed, N. Abdelhamid, et al., Prior asymptomatic parenchymal hemorrhage does not increase the risk for intracranial hemorrhage after intravenous thrombolysis, *Cerebrovasc. Dis.* 40 (5–6) (2015) 201–204.
- [100] A. Mowla, K. Singh, S. Mehla, M.K. Ahmed, P. Shirani, H. Kamal, et al., Is acute reperfusion therapy safe in acute ischemic stroke patients who harbor unruptured intracranial aneurysm? *Int. J. Stroke* 10 (2015) 113–118. Suppl A100.
- [101] H. Kamal, A. Mowla, S. Farooq, P. Shirani, Recurrent ischemic stroke can happen in stroke patients very early after intravenous thrombolysis, *J. Neurol. Sci.* 358 (1–2) (2015) 496–497.
- [102] K. Singh, A. Mowla, S. Mehla, M.K. Ahmed, P. Shirani, W.E. Zimmer, et al., Safety of intravenous thrombolysis for acute ischemic stroke in patients with preexisting intracranial neoplasms: a case series, *Int. J. Stroke* 10 (3) (2015) E29–E30.
- [103] A. Mowla, H. Shah, N.S. Lail, P. Shirani, Successful intravenous thrombolysis for acute stroke caused by polycythemia vera, *Arch. Neurosci.* 4 (4) (2017) e62181.
- [104] A. Mowla, H. Kamal, S. Mehla, P. Shirani, R.N. Sawyer, Rate, clinical features, safety profile and outcome of intravenous thrombolysis for acute ischemic stroke in patients with negative brain imaging, *J. Neurol. Res.* 10 (4) (Aug 2020), 2020.
- [105] A. Alrohani, K. Purdy, M. Alqarni, G. Alotaibi, G. Blevins, K. Butcher, et al., The clinical conundrum of managing ischemic stroke in patients with immune thrombocytopenia, *Can. J. Neurol. Sci.* 48 (1) (2021) 38–46.
- [106] R.C. Seet, A.A. Rabinstein, Symptomatic intracranial hemorrhage following intravenous thrombolysis for acute ischemic stroke: a critical review of case definitions, *Cerebrovasc. Dis.* 34 (2) (2012) 106–114.
- [107] A. Mowla, J. Doyle, N.S. Lail, H. Rajabzadeh-Oghaz, C. Deline, P. Shirani, et al., Delays in door-to-needle time for acute ischemic stroke in the emergency department: a comprehensive stroke center experience, *J. Neurol. Sci.* 376 (2017) 102–105.
- [108] J. Kenda, D. Lovrić, M. Škerget, M. Milivojević, Treatment of ChAdOx1 nCoV-19 vaccine-induced immune thrombotic thrombocytopenia related acute ischemic stroke, *J. Stroke Cerebrovasc. Dis.* 30 (11) (2021), 106072.
- [109] A. Mowla, S.M. Razavi, N.S. Lail, P. Mohammadi, P. Shirani, K.S. Kavak, et al., Hyperdense middle cerebral artery sign and response to combination of mechanical Thrombectomy plus intravenous thrombolysis in acute stroke patients, *J. Neurol. Sci.* 429 (2021), 117618.
- [110] M. De Michele, M. Iacobucci, A. Chistolini, E. Nicolini, F. Pulcinelli, B. Cerbelli, et al., Malignant cerebral infarction after ChAdOx1 nCoV-19 vaccination: a catastrophic variant of vaccine-induced immune thrombotic thrombocytopenia, *Nat. Commun.* 12 (1) (2021) 4663.
- [111] G. Costentin, O. Ozkul-Wermester, A. Triquenot, V.L. Cam-Duchez, N. Massy, Y. Benhamou, et al., Acute ischemic stroke revealing ChAdOx1 nCoV-19 vaccine-induced immune thrombotic thrombocytopenia: impact on recanalization strategy, *J. Stroke Cerebrovasc. Dis.* 30 (9) (2021), 105942.
- [112] M. Garnier, A. Curado, P. Billoir, V. Barbay, M. Demeyere, J.-N. Dacher, Imaging of Oxford/AstraZeneca® COVID-19 vaccine-induced immune thrombotic thrombocytopenia, *Diagn. Interv. Imaging* 102 (10) (2021) 649–650.
- [113] A. Cascio Rizzo, G. Giussani, E.C. Agostoni, Ischemic stroke and vaccine-induced immune thrombotic thrombocytopenia following COVID-19 vaccine: a case report with systematic review of the literature, *Cerebrovasc. Dis. (Basel, Switzerland)* (2022) 1–13.
- [114] M.A. Alammari, Ischemic stroke after AstraZeneca (Covid-19) vaccination, *Saudi Med. J.* 42 (10) (2021) 1136–1139.
- [115] A. Bayas, M. Menacher, M. Christ, L. Behrens, A. Rank, M. Naumann, Bilateral superior ophthalmic vein thrombosis, ischaemic stroke, and immune thrombocytopenia after ChAdOx1 nCoV-19 vaccination, *Lancet.* 397 (10285) (2021), e11.
- [116] G. Berlot, A. Tomasini, C. La Fata, S. Pintacuda, S. Rigutti, A. Falanga, Widespread arterial thrombosis after ChAdOx1 nCoV-19 vaccination, *Case Rep. Crit. Care* 2022 (2022) 6804456.
- [117] R.A. Blauenfeldt, S.R. Kristensen, S.L. Ernsten, C.C.H. Kristensen, C.Z. Simonsen, A.M. Hvas, Thrombocytopenia with acute ischemic stroke and bleeding in a patient newly vaccinated with an adenoviral vector-based COVID-19 vaccine, *J. Thromb. Haemost.* 19 (7) (2021) 1771–1775.
- [118] N. Ceschia, V. Scheggi, A.M. Gori, A.A. Rogolino, F. Cesari, B. Giusti, et al., Diffuse prothrombotic syndrome after ChAdOx1 nCoV-19 vaccine administration: a case report, *J. Med. Case Rep.* 15 (1) (2021) 496.
- [119] D.G. Corrêa, L.A.Q. Cañete, G.A.C. Dos Santos, R.V. de Oliveira, C.O. Brandão, L. C.H. da Cruz, Jr., Neurological symptoms and neuroimaging alterations related with COVID-19 vaccine: cause or coincidence? *Clin. Imaging* 80 (2021) 348–352.

- [120] A. Wills, G. Swallow, M.A. Kirkman, K. Rajan, G. Subramanian, Arterial and venous thrombotic stroke after ChAdOx1 nCoV-19 vaccine, *Clin. Med. (Lond)*. 22 (2) (2022) 184–186.
- [121] A. Tiede, U.J. Sachs, A. Czwalińska, S. Werwitzke, R. Bikker, J.K. Krauss, et al., Prothrombotic immune thrombocytopenia after COVID-19 vaccination, *Blood*. 138 (4) (2021) 350–353.
- [122] U. Walter, M. Fuchs, A. Grossmann, M. Walter, T. Thiele, A. Storch, et al., Adenovirus-vectored COVID-19 vaccine-induced immune thrombosis of carotid artery: a case report, *Neurology*. 97 (15) (2021) 716–719.
- [123] M. George, N. Baby, A. Azad, A. Rajan, S.K. Radhakrishnan, Neurological disorders seen during second wave of SARS-CoV-2 pandemic from two tertiary care centers in central and southern Kerala, *Ann. Indian Acad. Neurol.* 24 (6) (2021) 917–926.
- [124] E. Pang, S. Ghosh, T. Chemmanam, C. Grove, T. Phillips, Cerebral arterial and venous thrombosis due to COVID-19 vaccine-induced immune thrombotic thrombocytopenia, *BMJ Case Rep.* 15 (1) (2022).
- [125] V. D'Agostino, F. Caranci, A. Negro, V. Piscitelli, B. Tuccillo, F. Fasano, et al., A rare case of cerebral venous thrombosis and disseminated intravascular coagulation temporally associated to the COVID-19 vaccine administration, *J Pers Med.* 11 (4) (2021).
- [126] A. Bourguignon, D.M. Arnold, T.E. Warkentin, J.W. Smith, T. Pannu, J.M. Shrum, et al., Adjunct immune globulin for vaccine-induced immune thrombotic thrombocytopenia, *N. Engl. J. Med.* 385 (8) (2021) 720–728.
- [127] A. Charidimou, S. Samudrala, A.M. Cervantes-Arslanian, J.M. Sloan, H. H. Dasenbrock, A. Daneshmand, Vaccine-induced immune thrombotic thrombocytopenia with concurrent arterial and venous thrombi following Ad26.COV2.S vaccination, *J. Stroke Cerebrovasc. Dis.* 30 (12) (2021), 106113.
- [128] R. Giovane, J. Campbell, Bilateral thalamic stroke: a case of COVID-19 vaccine-induced immune thrombotic thrombocytopenia (VITT) or a coincidence due to underlying risk factors? *Cureus*. 13 (10) (2021), e18977.
- [129] K. Yoshida, K. Tanaka, Y. Suto, H. Fukuda, Repeated cardioembolic stroke after COVID-19 mRNA vaccination: a case report, *J. Stroke Cerebrovasc. Dis.* 31 (2) (2022) 106233.