



Contents lists available at ScienceDirect

AACE Clinical Case Reports

journal homepage: www.aaceclinicalcasereports.com

Case Report

A Case of Hypophysitis Associated With SARS-CoV-2 Vaccination

Anvitha R. Ankireddypalli, MD¹, Lisa S. Chow, MD, MS¹, Angela Radulescu, MD¹,
Yasuhiko Kawakami, PhD^{2,3}, Takako Araki, MD^{1,*}¹ Division of Diabetes, Endocrinology and Metabolism, Department of Medicine, University of Minnesota, Minneapolis, Minnesota² Department of Genetics, Cell Biology and Development, University of Minnesota, Minneapolis, Minnesota³ Stem Cell Institute, University of Minnesota, Minneapolis, Minnesota

ARTICLE INFO

Article history:

Received 13 January 2022

Received in revised form

1 June 2022

Accepted 9 June 2022

Available online xxx

Key words:

SARS-CoV-2 vaccination

hypophysitis

diabetes insipidus

endocrinopathy

ABSTRACT

Background/Objective: Although SARS-CoV-2 vaccines have been developed with multiple novel technologies and rapidly disseminated worldwide, the full profile of adverse effects has not been known. Recently, there are sporadic but increasing reports of endocrinopathy in relation to SARS-CoV-2 vaccination. Here we report a rare case of hypophysitis with acute onset of diabetes insipidus, immediately after SARS-CoV-2 vaccination.

Case Report: A 48-year-old female patient had been in her usual state of health until she received the first SARS-CoV-2 vaccine. Two days after vaccination, she started to have flu-like symptoms, including severe headache and myalgia as well as persistent headache, polydipsia, and polyuria. She was diagnosed with diabetes insipidus, and magnetic resonance imaging revealed thickening of the pituitary stalk. Three months after vaccination, her symptoms had somewhat improved, but she still had pituitary stalk thickening on magnetic resonance imaging.

Discussion: Given the timing of the occurrence of diabetes insipidus, we believe that the patient's hypophysitis may be associated with SARS-CoV-2 vaccination. We also found 19 cases of endocrinopathy after SARS-CoV-2 vaccination by literature search. The reported endocrine organs were the thyroid, pituitary, and adrenals. Twelve cases of diabetes were also reported. Among 3 pituitary cases, diabetes insipidus was reported only in our case.

Conclusion: We report a rare case of SARS-CoV-2 vaccine-triggered hypophysitis, which led to diabetes insipidus. SARS-CoV-2 vaccine-related endocrinopathy seems, indeed, possible. Endocrinopathy is associated with infrequent complications; however, it may be underestimated in the post-SARS-CoV-2-vaccinated population. Further studies are warranted to better understand SARS-CoV-2 vaccine-related endocrinopathy.

© 2022 AACE. Published by Elsevier Inc. This is an open access article under the CC BY-NC-ND license (<http://creativecommons.org/licenses/by-nc-nd/4.0/>).

Introduction

After the development and approval of vaccines against SARS-CoV-2, the dissemination has been rapid and worldwide.^{1,2} Multiple novel technologies have been used to develop SARS-CoV-2 vaccines, including messenger ribonucleic acid vaccines (Pfizer and Moderna), adenovirus vector vaccines (AstraZeneca and Johnson & Johnson), inactivated vaccines (Sinovac and Bharat), and

modified adjuvant vaccines.¹ These vaccines have been authorized for use in humans by multiple regulating bodies, including the U.S. Food and Drug Administration (Pfizer-BioNTech, Moderna, and Johnson & Johnson), European Medicines Agency (AstraZeneca), or other health ministries. Typically, the adverse side effects of vaccination include transient headache, fever, and myalgia.

Endocrine cells seem to be susceptible to acute elevation of the cytokine levels, which may cause endocrinopathy,^{3,4} although the exact mechanism underlying this phenomenon remains unclear. For example, endocrinopathies were reported after cancer immunotherapy, which is known to elevate the cytokine levels. Specifically, administration of ipilimumab (a CTLA-4 inhibitor) increases the circulating tumor necrosis factor- α levels, and administration of nivolumab (a PD-1 inhibitor) increases both the tumor necrosis factor- α and interleukin 6 levels in treated patients. The endocrine

Abbreviations: IGF1, insulin-like growth factor 1; IgG, immunoglobulin G; MRI, magnetic resonance imaging.

* Address correspondence to Dr Takako Araki, Division of Diabetes, Endocrinology and Metabolism, University of Minnesota, 516 Delaware Street, SE, Minneapolis, MN 55455.

E-mail address: araki@umn.edu (T. Araki).

<https://doi.org/10.1016/j.aace.2022.06.001>

2376-0605/© 2022 AACE. Published by Elsevier Inc. This is an open access article under the CC BY-NC-ND license (<http://creativecommons.org/licenses/by-nc-nd/4.0/>).

organs involved in these immunotherapy-associated endocrinopathies are the thyroid, pituitary, and adrenals.^{5,6} Interestingly, it is reported that SARS-CoV-2 vaccines also induce acute cytokine release.⁷ Therefore, it is conceivable to hypothesize that SARS-CoV-2 vaccination can cause endocrinopathies, although the frequency is unknown. In agreement with this hypothesis, possible associations of SARS-CoV-2 vaccination and endocrinopathies have been sporadically reported worldwide.⁸⁻²¹ Here, we report a rare case of hypophysitis with acute onset of diabetes insipidus, immediately after SARS-CoV-2 vaccination. We also review the reported endocrinopathies, which occurred after SARS-CoV-2 vaccination.

Case Report

A 48-year-old female patient with a past medical history of obesity had been in her usual state of health until she received the first SARS-CoV-2 vaccine (BNT162b2; Pfizer-BioNTech) on May 21, 2021. Two days after vaccination, she started to have flu-like symptoms, including severe headache and myalgia. She also noticed excessive thirst and urination at the same time. Prior to vaccination, she has never had an episode of polyuria and polydipsia. Myalgia was resolved by 2 weeks, but headache, polydipsia, and polyuria persisted. She visited a primary care clinic to seek medical attention; however, she was told that the symptoms could be the general side effects of SARS-CoV-2 vaccination and would resolve over time. When she received the second SARS-CoV-2 vaccine (BNT162b2; Pfizer-BioNTech) on June 27, 2021, she still reported persistent polydipsia, polyuria, headache, and lethargy. The day after her second vaccination, the patient reported exacerbation of polyuria and polydipsia, with urinary frequency every hour. The daily urinary output was approximately 4 L. She also noted worsened headache, excessive fatigue, and multijoint pain. She reported a significant weight loss of a total of 18 kg since the first vaccination. She finally presented to the emergency department of our medical center on August 27, 2021 for increasing fatigue, intolerable polydipsia, polyuria, headache with nausea, emesis, and light-headedness. She denied syncopal episodes, vision changes, and altered mental status. Upon history taking, she admitted no menses since the first vaccination. Prior to that, her menses had been regular. Her family history was unremarkable for autoimmune disease.

On presentation, her vital signs were stable: (1) pulse rate, 81/m; (2) blood pressure, 122/84 mm Hg; and (3) temperature, 98.6 °F. Physical examination was unremarkable. The input and output during 8 hours of stay in the emergency department were markedly discrepant with 0.4 L of intake and 2.2 L of urine output. Laboratory evaluation revealed normal values of basic metabolic panels, including a sodium level of 142 mmol/L (reference, 133–144 mmol/L) and normal complete blood cell count (Table 1). Because of prolonged and worsening headache, she underwent brain magnetic resonance imaging (MRI) (Fig. A), which revealed a 4-mm, round, thickened pituitary stalk (Fig. A, yellow arrow). In addition, MRI showed a partially empty sella (Fig. A, red arrow). Polydipsia, polyuria, and pituitary stalk thickening led us to further analyze her pituitary workup. Pituitary biopsy was not performed because of patient preference and difficulty in accessing the organ. The initial serum osmolality was elevated (306 mmol/kg; reference, 275–295 mmol/kg), whereas the urine osmolality was low (97 mmol/kg; reference, 100–1200 mmol/kg) (Table 2). Pituitary hormone workup revealed that the insulin-like growth factor 1 (IGF1) level was lower than the normal range (66 ng/mL; reference, 60–240 ng/mL). Considering her age, the follicle-stimulating hormone and luteinizing hormone levels were low (5.2 IU/L and 2.6 IU/L, respectively); however, the estradiol level was within the normal range (307 pg/

Highlights

- We report a rare case of SARS-CoV-2 vaccination –associated hypophysitis
- SARS-CoV-2 vaccination—associated endocrinopathy has been sporadically reported
- Endocrinopathy may be underestimated in the post –SARS-CoV-2-vaccinated population

Clinical Relevance

We report a rare case of hypophysitis with acute onset of diabetes insipidus, immediately after SARS-CoV-2 vaccination. We also summarized all currently published cases of SARS-CoV-2–related endocrinopathy and described them by onset, age, sex, and clinical course. We believe that SARS-CoV-2 vaccine–related endocrinopathy would be warranted further attention.

mL). The human chorionic gonadotropin level was undetectable. The thyroid axis and prolactin levels were within the normal range (Table 2). The 250-mcg cosyntropin test showed appropriate response without adrenal insufficiency (Table 2). During hospitalization, she underwent the overnight water deprivation test followed by the desmopressin challenge test (Table 2 and Fig. C). The overnight water deprivation test showed hypernatremia (sodium level, 147 mmol/L; reference, 133–144 mmol/L), elevated serum osmolality (309 mmol/kg; reference, 275–295 mmol/kg), and low urine osmolality (83 mmol/kg; reference, 100–1200 mmol/kg), which were compatible with diabetes insipidus. After subcutaneous administration of 2-mcg desmopressin, hypernatremia improved (sodium level, 139 mmol/L; reference, 133–144 mmol/L), and the

Table 1
Nonendocrine Test Laboratory Values Upon Hospitalization

Laboratory parameter	Value	Reference value
Sodium	142 mmol/L	133–144 mmol/L
Potassium	4.2 mmol/L	3.4–5.3 mmol/L
Chloride	108 mmol/L	94–109 mmol/L
CO ₂	30 mmol/L	20–32 mmol/L
BUN	5 mg/dL	7–30 mg/dL
Creatinine	0.73 mg/dL	0.52–1.04 mg/dL
Glucose	105 mg/dL	70–99 mg/dL
Calcium	9.6 mg/dL	8.5–10.1 mg/dL
Phosphorus	3.4 mg/dL	2.5–4.5 mg/dL
Magnesium	2.2 mg/dL	1.6–2.3 mg/dL
AST	29 U/L	0–45 U/L
ALT	29 U/L	0–50 U/L
WBC	8.3 × 10e3/uL	4.0–11.0 × 10e3/uL
Hemoglobin	13.6 g/dL	11.7–15.7 g/dL
Hematocrit	45.40%	35.0%–47.0%
Platelet count	306 × 10e3/uL	150–450 × 10e3/uL
CRP	23.0 mg/L	0.0–8.0 mg/L
ESR	34 mm/h	0–20 mm/h
Ferritin	14 ng/mL	8–252 ng/mL
ACE	23 U/L	9–67 U/L
hCG	Negative	Negative
IgG1	569 mg/dL	383–929 mg/dL
IgG2	368 mg/dL	242–700 mg/dL
IgG3	73 mg/dL	22–176 mg/dL
IgG4	27 mg/dL	4–86 mg/dL

Abbreviations: ACE = angiotensin-converting enzyme; ALT = alanine aminotransferase; AST = aspartate aminotransferase; BUN = blood urea nitrogen; CO₂ = carbon dioxide; CRP = C-reactive protein; ESR = erythrocyte sedimentation rate; hCG = human chorionic gonadotropin; IgG = immunoglobulin G; WBC = white blood cell.

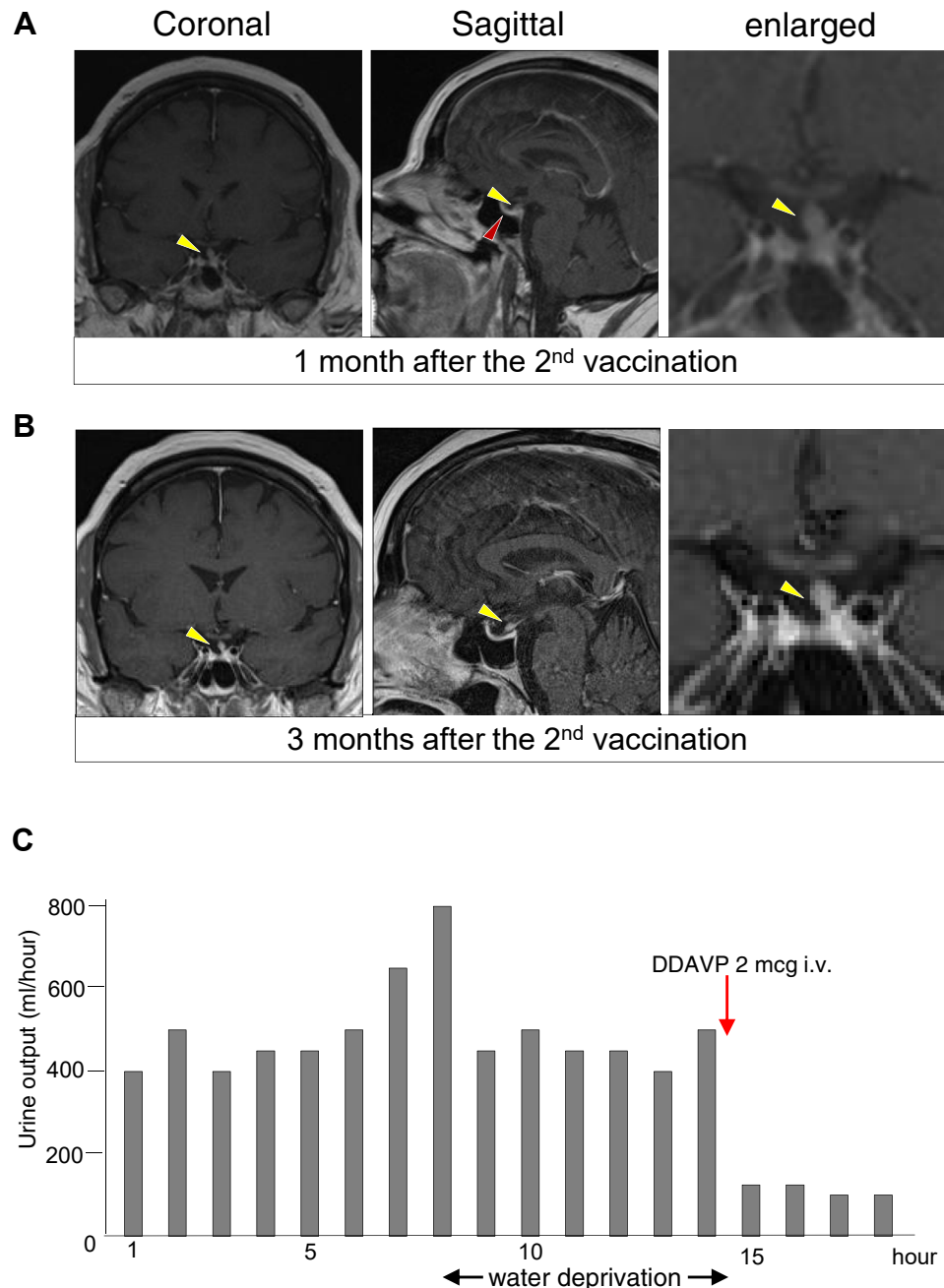


Fig. Brain magnetic resonance imaging. Brain sagittal (left) and coronal (right) T1-weighted MR images with gadolinium contrast. **A**, The MR images after the second vaccine show pituitary stalk thickening (yellow arrow) and a partially empty sella (red arrow). **B**, The MR images 3 months after hospitalization show unchanged pituitary stalk thickening (yellow arrow) and a partially empty sella (red arrow). **C**, Hourly urine output during the water deprivation test. The x-axis shows the time after hospitalization. Each bar represents urine output in each hour. The red arrow indicates the timing of DDAVP administration.

urine concentration increased (urine osmolality, 468 mmol/kg; reference, 100-1200 mmol/kg). With these test results, we confirmed the diagnosis of central diabetes insipidus. Other relevant laboratory workup results included increased levels of the following 2 inflammatory markers: (1) C-reactive protein (23 mg/L; reference, 0.0-8.0 mg/L) and (2) erythrocyte sedimentation rate (34 mm/h; reference, 0-20 mm/h) (Table 1). The levels of immunoglobulin G (IgG) and its subclasses (IgG1 to IgG4), serum angiotensin-converting enzyme, and ferritin were within the normal ranges, and the result of chest radiography was negative. She was discharged with a fixed dose of 10 mcg of DDAVP nasal sprays twice a day. With the DDAVP use, her symptoms of polyuria and polydipsia markedly improved. Two months after hospitalization, the patient

underwent repeat brain MRI, which showed a persistently thickened pituitary stalk (Fig. B). At present, she still requires DDAVP intranasal sprays 10 mcg twice a day to manage her symptoms. The IGF1 level has improved to the midnormal range 5 months after vaccination (Table 2). Her amenorrhea has resolved 5 months after the second vaccination. Although her symptoms have improved, she still experiences some fatigue, joint pain, and brain foginess. She has regained part of the weight lost.

Discussion

SARS-CoV-2 vaccines have been rapidly developed with several novel and conventional technologies.^{1,2} Although there are widely

Table 2
Endocrine Test Laboratory Values

Pituitary hormones				
After vaccination	1 mo	3 mo	5 mo	Reference value
IGF1	66 ng/mL	89 ng/mL	125 ng/mL	60-240 ng/mL
TSH	2.66 mU/L	3.08 mU/L	2.48 mU/L	0.4-4.00 mU/L
Free T4	0.88 ng/dL	0.88 ng/dL	0.96 ng/dL	0.76-1.46 ng/dL
Prolactin	23 ug/L	19 ug/L	15 ug/L	3-27 ug/L
LH	2.6 IU/L	2.6 IU/L	4.3 IU/L	23-116.3 U/L
FSH	5.2 IU/L	5.3 IU/L	5.4 IU/L	15.9-54 U/L
Estradiol	307 pg/mL	N/A	N/A	Follicular, 90-590 pg/mL Luteal, 50-170 pg/mL
Cosyntropin stimulation test during hospitalization				
	0 min	30 min	60 min	Reference value
ACTH	26 pg/mL			<47 pg/mL
Cortisol	7.6 ug/dL	17.8 ug/dL	20.7 ug/dL	4.0-22.0 ug/dL
Water deprivation test during hospitalization				
	Before the test	Water deprivation	Desmopressin challenge	Reference value
Serum sodium	142 mmol/L	147 mmol/L	139 mmol/L	133-144 mmol/L
Serum osmolality	306 mmol/kg	309 mmol/kg	209 mmol/kg	275-295 mmol/kg
Urine osmolality	97 mmol/kg	83 mmol/kg	468 mmol/kg	100-1200 mmol/kg

Abbreviations: ACTH = adrenocorticotropic hormone; FSH = follicle-stimulating hormone; IGF1 = insulin-like growth factor 1; LH = luteinizing hormone; T4 = thyroxine; TSH = thyroid-stimulating hormone.

known side effects of SARS-CoV-2 vaccination, including headache, fever, and myalgia, the full profile of adverse effects is yet to be elucidated. There are sporadic but increasing reports of endocrinopathy, which occurred after SARS-CoV-2 vaccination. According to our English literature search, 19 cases of post-SARS-CoV-2 vaccination endocrinopathy have been reported (Table 3).⁸⁻²¹ Among them, the majority of the cases involved the thyroid (15/19 cases, 79%), 1 (5%) case involved the adrenal gland, and 3 (16%) cases, including our case, involved the pituitary. The mean age of these patients was 46 years, and 78% of them were women. In all cases, the patients were relatively healthy prior to vaccination, except 1 patient who was on treatment of colon cancer.¹⁹ With respect to the types of vaccines, endocrinopathy was reported in all 3 types of vaccines; 9 (47%) cases involved messenger ribonucleic acid vaccines, 6 (32%) cases involved adenovirus vector vaccines, and 4 (21%) cases involved inactivated vaccines. The majority of the cases (n = 13, 68%) occurred acutely in 1 to 5 days after vaccination. In 4 cases, subacute onset of thyroiditis 2 to 3 weeks after vaccination was reported. In 3 cases, including our case, the second vaccine dose was administered despite the onset of symptoms following the first vaccine dose, and the initial symptoms worsened. In patients with diabetes, sporadic cases are reported, in which glucose level control acutely worsened after SARS-CoV-2 vaccination (Table 4).²²⁻²⁸ Among them, some patients presented with diabetes ketoacidosis or hyperglycemic hyperosmolar state. Eight of 12 reported cases of diabetes involved middle-aged men. However, 2 recent observational studies demonstrated that SARS-CoV-2 vaccination only minimally impacted glycemic control in patients with diabetes.^{27,28}

The natural course and prognosis of these endocrinopathies after SARS-CoV-2 vaccination remain unknown. Among the cases involving the thyroid, 7 (47%) were reported as full recovery after 1 to 3 months.^{8-10,16,17} In contrast, 6 cases (40%) with the thyroid were not fully recovered at the time of reports. With respect to 3 pituitary cases, 2, including our case, showed partial recovery in 1¹² or 5 months. For patient management, steroids were administered in 4 cases for prolonged thyroiditis.^{8,9,16,17}

The mechanism of endocrinopathies after SARS-CoV-2 vaccination is unknown. One potential mechanism would involve acute elevation of the cytokine levels. Endocrine cells seem to be

susceptible to acute elevation of the cytokine levels, as reported in cancer immunotherapy-associated endocrinopathy.^{5,6} It has been reported that SARS-CoV-2 vaccination can cause cytokine release syndrome.⁷ Therefore, we speculate that the vaccination may have caused acute changes in the cytokine levels, which led to disruption of endocrine functions. However, the onset of SARS-CoV-2 vaccination-associated endocrinopathy is more acute than that of immunotherapy-associated endocrinopathy, whose onset usually takes more than several weeks.^{5,6} Another suggested mechanism for post-SARS-CoV-2 vaccination thyroiditis is cross-reaction of the SARS-CoV-2 spike protein antibody and thyroid peroxidase antibody.²⁹ Furthermore, it is possible that vaccination may have triggered underlying conditions in susceptible subjects.

Regarding endocrinopathy involving the pituitary, 3 cases have been reported. These cases had different clinical presentations (Table 3). Our case presented with pituitary stalk thickening and diabetes insipidus. The second case presented with hypopituitarism (secondary adrenal insufficiency and hypothyroidism) with enlargement of the pituitary gland without diabetes insipidus.¹² The third case presented with hemorrhagic pituitary apoplexy without pituitary hormone deficiency.²¹

In our case, 4 important points were noted for differential diagnosis. First, the broad differential diagnosis of the cause of pituitary stalk thickening needed to be considered.³⁰ In our initial workup, we ruled out the following: (1) germinoma by an undetectable human chorionic gonadotropin level, (2) sarcoidosis by a low angiotensin-converting enzyme level and negative chest radiographic result, and (3) autoimmune hypophysitis by a normal IgG level. The second point of differential diagnosis was the partially empty sella. This may be because of the following: (1) elevated body mass index;³¹ (2) underlying pituitary conditions, although there was no significant past medical or family history; or (3) the effect of SARS-CoV-2 vaccination. The third point was the low IGF1 level. This could be because of the high body mass index³¹ or effect of SARS-CoV-2 vaccination. We speculate that our case is likely SARS-CoV-2 vaccine-related rather than because of the high body mass index. This interpretation is based on the observation that the low IGF1 level was transient and the level returned to normal 5 months after vaccination (Table 2). The last interesting point was transient amenorrhea. Upon initial evaluation, the

Table 3
Summary of the Reported Cases of Endocrinopathy After SARS-CoV-2 Vaccination

Endocrine organ (ref)	Age and sex (M/F)	Product	Type of vaccines	Onset after vaccination	Endocrinopathy/symptoms	Clinical course
Pituitary	48 y, F (current case)	BNT162b2 (Pfizer-BioNTech)	mRNA	2 d	Hypophysitis/polyuria, polydipsia, headache	Partial improvement
Pituitary ¹²	51 y, M	Spikevax (Moderna)	mRNA	2-3 d	Hypopituitarism/nausea, vomiting, abdominal pain	Spontaneous improvement
Pituitary ²¹	37 y, F	Vaxzevria (AstraZeneca)	Adenovirus vector	5 d	Apoplexy/sudden headache, hemorrhagic adenoma	No pituitary hormone abnormalities, spontaneous recovery in 2-3 wk
Adrenal ²⁰	47 y, M	Vaxzevria (AstraZeneca)	Adenovirus vector	1 d	Adrenal insufficiency/neurologic symptoms, thrombocytopenia	N/A
Thyroid ¹⁷	57 y, F	BNT162b2 (Pfizer-BioNTech)	mRNA	1 d	Hyperthyroidism/fever, thyrotoxicosis	Symptoms started after the first dose and then worsened after the second dose
Thyroid ¹⁰	26 y, F	Vaxzevria (AstraZeneca)	Adenovirus vector	2 d	Hyperthyroidism/neck pain, palpitation	Full recovery at 6 wk
Thyroid ¹¹	35 y, F	CoronaVac (Sinovac)	Inactivated	4 d	Hyperthyroidism/fever, neck pain, fatigue	Developed after the second dose, euthyroid after 1 mo of steroid
Thyroid ¹¹	34 y, F	CoronaVac (Sinovac)	Inactivated	4 d	Fever, neck pain, fatigue	SARS-CoV-2 infection prior to vaccination, on steroid 1 mo, symptoms persisted
Thyroid ¹³	42 y, F	BNT162b2 (Pfizer-BioNTech)	mRNA	4 d	Fever, neck pain, palpitation	Symptoms started after the first dose and then worsened after the second dose
Thyroid ¹⁸	51 y, F	BNT162b2 (Pfizer-BioNTech)	mRNA	4 d	Fever, neck pain, nausea	Methimazole and steroid were administered, euthyroid at 2 mo
Thyroid ²²	42 y, F	BNT162b2 (Pfizer-BioNTech)	mRNA	5 d	Hyperthyroidism/sore throat, palpitation	Symptoms started after the first dose
Thyroid ¹⁹	34 y, F	Covaxin (Bharat Biotech)	Inactivated	5 d	Hyperthyroidism/fever, neck pain, palpitation	Steroid administered, euthyroid at 7 wk
Thyroid ²¹	42 y, F	Spikevax (Moderna)	mRNA	5 d	Ear pain, dysphagia	Symptoms resolved but hypothyroidism at 2 mo
Thyroid ¹⁰	49 y, F	Spikevax (Moderna)	mRNA	1 wk	Sore throat, headache	Still on prednisone 1 mo after
Thyroid ¹¹	37 y, F	CoronaVac (Sinovac)	Inactivated	1 wk	Neck pain	Developed after the second dose, spontaneous recovery at 2 mo
Thyroid ¹⁶	75 y, M	Vaxzevria (AstraZeneca)	Adenovirus vector	2 wk	Hyperthyroidism/neck pain, palpitation	Symptoms persisted at 3 mo
Thyroid ¹⁴	Middle age, F	BNT162b2 (Pfizer-BioNTech)	mRNA	2 wk	Neck pain	Euthyroid at 3 mo
Thyroid ¹⁵	55 y, F	Vaxzevria (AstraZeneca)	Adenovirus vector	3 wk	Headache, sore throat, palpitation	Subacute thyroiditis, hypothyroidism persisted at 4 mo
Thyroid ¹⁸	39 y, F	Vaxzevria (AstraZeneca)	Adenovirus vector	3 wk	None	Euthyroid at 2 mo

Abbreviations: F = female; M = male; mRNA = messenger ribonucleic acid; N/A = not available.

luteinizing hormone and follicle-stimulating hormone levels were relatively low, whereas the estradiol level was within the normal range (Table 2). Given that SARS-CoV-2 vaccination can induce acute changes in the cytokine levels,⁷ we speculate that her

postvaccination amenorrhea could be functional hypothalamic amenorrhea because of acute stress owing to SARS-CoV-2 vaccination or possibly mild and transient central hypogonadism.³² Interestingly, transient menstrual irregularity after SARS-CoV-2

Table 4
Summary of the Reported Cases of Hyperglycemia After SARS-CoV-2 Vaccination

Pre-existing condition	Age and sex (M/F)	Product	Type of vaccines	Onset after vaccination	Presentation	Comments (ref)
Unknown	58 y, M	BNT162b2 (Pfizer-BioNTech)	mRNA	N/A	HHS	Onset after the first dose, worsened after the second dose ²⁴
None	59 y, M	Vaxzevria (AstraZeneca)	Adenovirus vector	<1 wk	HHS	Mishra et al ²⁵
Pre-DM	53 y, M	Vaxzevria (AstraZeneca)	Adenovirus vector	<1 wk	HHS and DKA	Mishra et al ²⁵
Pre-DM	68 y, M	Vaxzevria (AstraZeneca)	Adenovirus vector	<1 wk	DKA	Mishra et al ²⁵
None	52 y, F	BNT162b2 (Pfizer-BioNTech)	mRNA	2 d	HHS	Ganakumar et al ²⁶
Type 2 DM	59 y, M	Spikevax (Moderna)	mRNA	2 d	HHS	Ganakumar et al ²⁶
Type 2 DM	87 y, M	Spikevax (Moderna)	mRNA	2 d	HHS and DKA	Complicated by aspiration pneumonia and DVT ²⁶
Type 2 DM	58 y, F	Covishield (AstraZeneca)	Adenovirus vector	1 d	None	Glucose level normalized in 1 mo ²⁷
[x] Type 2 DM	64 y, M	Covishield (AstraZeneca)	Adenovirus vector	1 d	None	Glucose level normalized in 3 d ²⁷
Type 2 DM	65 y, M	Covishield (AstraZeneca)	Adenovirus vector	6 d	None	Glucose level normalized in 15 d ²⁷
Type 1 DM	20 y, M	Covishield (AstraZeneca)	Adenovirus vector	3 d	DKA	Heald et al ²⁸
Type 1 DM	25 y, F	Covaxin (Bharat Biotech)	Inactivated	4 d	DKA	Heald et al ²⁸

Abbreviations: DKA = diabetes ketoacidosis; DM = diabetes mellitus; DVT = deep venous thrombosis; F = female; HHS = hyperglycemic hyperosmolar state; M = male; mRNA = messenger ribonucleic acid; N/A = not available.

vaccination has been reported in up to 60% of reproductive-age women.^{33,34}

Conclusion

We report a rare case of possible SARS-CoV-2 vaccine-related hypophysitis, which led to diabetes insipidus. Endocrinopathy after SARS-CoV-2 vaccination is, indeed, possible. Endocrinopathy is associated with infrequent complications; however, it may be underestimated in the post-SARS-CoV-2-vaccinated population. Further studies are warranted to better understand endocrinopathy and its possible association with SARS-CoV-2 vaccination.

Acknowledgment

This study was supported by grants from the University of Minnesota (UMF0011528 to T.A., AHC Grant-in-Aid 212588 to T.A.) and a grant from the National Institutes of Health (R01DK130378 to T.A. and Y.K.).

Disclosure

The authors have no multiplicity of interest to disclose.

References

- Crech CB, Walker SC, Samuels RJ. SARS-CoV-2 vaccines. *JAMA*. 2021;325(13):1318–1320.
- Kyriakidis NC, López-Cortés A, González EV, Grimaldos AB, Prado EO. SARS-CoV-2 vaccines strategies: a comprehensive review of phase 3 candidates. *NPJ Vaccines*. 2021;6(1):28.
- Arzt E, Pereda MP, Castro CP, Pagotto U, Renner U, Stalla GK. Pathophysiological role of the cytokine network in the anterior pituitary gland. *Front Neuroendocrinol*. 1999;20(1):71–95.
- Leal AM, Magalhães PK, Souza CS, Foss NT. Pituitary-gonadal hormones and interleukin patterns in leprosy. *Trop Med Int Health*. 2006;11(9):1416–1421.
- Postow MA, Sidlow R, Hellmann MD. Immune-related adverse events associated with immune checkpoint blockade. *N Engl J Med*. 2018;378(2):158–168.
- Takahashi Y. Mechanisms in endocrinology: autoimmune hypopituitarism: novel mechanistic insights. *Eur J Endocrinol*. 2020;182(4):R59–R66.
- Au L, Fendler A, Shepherd STC, et al. Cytokine release syndrome in a patient with colorectal cancer after vaccination with BNT162b2. *Nat Med*. 2021;27(8):1362–1366.
- Bornemann C, Woyk K, Bouter C. Case report: two cases of subacute thyroiditis following SARS-CoV-2 vaccination. *Front Med (Lausanne)*. 2021;8, 737142.
- İremli BG, Şendur SN, Ünlütürk U. Three cases of subacute thyroiditis following SARS-CoV-2 vaccine: postvaccination ASIA syndrome. *J Clin Endocrinol Metab*. 2021;106(9):2600–2605.
- Jeeyavudeen MS, Patrick AW, Gibb FW, Dover AR. COVID-19 vaccine-associated subacute thyroiditis: an unusual suspect for de Quervain's thyroiditis. *BMJ Case Rep*. 2021;14(11), e246425.
- Khan F, Brassill MJ. Subacute thyroiditis post-Pfizer-BioNTech mRNA vaccination for COVID-19. *Endocrinol Diabetes Metab Case Rep*. 2021;2021. <https://doi.org/10.1530/EDM-21-0142>, 21-0142.
- Murvelashvili N, Tessnow A. A case of hypophysitis following immunization with the mRNA-1273 SARS-CoV-2 vaccine. *J Investig Med High Impact Case Rep*. 2021;9, 23247096211043386.
- Oyibo SO. Subacute thyroiditis after receiving the adenovirus-vectored vaccine for coronavirus disease (COVID-19). *Cureus*. 2021;13(6), e16045.
- Ratnayake GM, Dworakowska D, Grossman AB. Can COVID-19 immunisation cause subacute thyroiditis? *Clin Endocrinol (Oxf)*. 2022;97(1):140–141.
- Schimmel J, Alba EL, Chen A, Russell M, Srinath R. Letter to the editor: thyroiditis and thyrotoxicosis after the SARS-CoV-2 mRNA vaccine. *Thyroid*. 2021;31(9):1440.
- Siolos A, Gartzonika K, Tigas S. Thyroiditis following vaccination against COVID-19: report of two cases and review of the literature. *Metabol Open*. 2021;12, 100136.
- Soltanpoor P, Norouzi G. Subacute thyroiditis following COVID-19 vaccination. *Clin Case Rep*. 2021;9(10), e04812.
- Varona JF, García-Isidro M, Moeinavaziri M, Ramos-López M, Fernández-Domínguez M. Primary adrenal insufficiency associated with Oxford-AstraZeneca ChAdOx1 nCoV-19 vaccine-induced immune thrombotic thrombocytopenia (VITT). *Eur J Intern Med*. 2021;91:90–92.
- Plaza-Enriquez L, Khatiwada P, Sanchez-Valenzuela M, Sikha A. A case report of subacute thyroiditis following mRNA COVID-19 vaccine. *Case Rep Endocrinol*. 2021;2021, 8952048.
- Franquemont S, Galvez J. Subacute thyroiditis after mRNA vaccine for COVID-19. *J Endocr Soc*. 2021;5(suppl 1):A956–A957.
- Piñar-Gutiérrez A, Remón-Ruiz P, Soto-Moreno A. Case report: pituitary apoplexy after COVID-19 vaccination. *Med Clin (Engl Ed)*. 2022;158(10):498–499.
- Abu-Rumailah MA, Gharaibeh AM, Gharaibeh NE. COVID-19 vaccine and hyperosmolar hyperglycemic state. *Cureus*. 2021;13(3), e14125.
- Edwards AE, Vathenen R, Henson SM, Finer S, Gunganah K. Acute hyperglycaemic crisis after vaccination against COVID-19: a case series. *Diabet Med*. 2021;38(11), e14631.
- Lee HJ, Sajan A, Tomer Y. Hyperglycemic emergencies associated with COVID-19 vaccination: a case series and discussion. *J Endocr Soc*. 2021;5(11):bvab141.
- Mishra A, Ghosh A, Dutta K, Tyagi K, Misra A. Exacerbation of hyperglycemia in patients with type 2 diabetes after vaccination for COVID19: report of three cases. *Diabetes Metab Syndr*. 2021;15(4), 102151.
- Ganakumar V, Jethwani P, Roy A, Shukla R, Mittal M, Garg MK. Diabetic ketoacidosis (DKA) in type 1 diabetes mellitus (T1DM) temporally related to COVID-19 vaccination. *Diabetes Metab Syndr*. 2022;16(1), 102371.
- Aberer F, Moser O, Aziz F, et al. Impact of COVID-19 vaccination on glycemia in individuals with type 1 and type 2 diabetes: substudy of the COVAC-DM study. *Diabetes Care*. 2022;45(2):e24–e26.
- Heald AH, Stedman M, Horne L, et al. The change in glycaemic control immediately after COVID-19 vaccination in people with type 1 diabetes. *Diabet Med*. 2022;39(4), e14774.
- Vojdani A, Kharrazian D. Potential antigenic cross-reactivity between SARS-CoV-2 and human tissue with a possible link to an increase in autoimmune diseases. *Clin Immunol*. 2020;217, 108480.
- Kim DY, Kim PH, Jung AY, et al. Neoplastic etiology and natural course of pituitary stalk thickening. *J Clin Endocrinol Metab*. 2022;107(2):563–574.
- De Marinis L, Bonadonna S, Bianchi A, Maira G, Giustina A. Primary empty sella. *J Clin Endocrinol Metab*. 2005;90(9):5471–5477.
- Gordon CM, Ackerman KE, Berga SL, et al. Functional hypothalamic amenorrhea: an Endocrine Society clinical practice guideline. *J Clin Endocrinol Metab*. 2017;102(5):1413–1439.
- Laganà AS, Veronesi G, Ghezzi F, et al. Evaluation of menstrual irregularities after COVID-19 vaccination: results of the MECOVAC survey. *Open Med (Wars)*. 2022;17(1):475–484.
- Edelman A, Boniface ER, Benhar E, et al. Association between menstrual cycle length and coronavirus disease 2019 (COVID-19) vaccination: a U.S. cohort. *Obstet Gynecol*. 2022;139(4):481–489.